

## Technical Note

# Modified Low-Flow Arthroscopic Sandwich Technique for Complex Osteochondral Lesions of the Talus

Hanna H. Sorensen, B.S., Adam G. F. Smith, B.S., Daniel J. Wagner, M.D., and Kevin D. Martin, D.O., F.A.A.O.S., F.A.A.N.A.

**Abstract:** Treatment of osteochondral lesions of the talus proves to be challenging given the unique anatomy of the intra-articular surface and associated complexity of larger lesions. Simple bone marrow–stimulating procedures for large complex lesions often lead to poor results with increased risk of lesion progression, refractory pain, and associated functional limitations. Other methods of osteochondral autografts or allografts often require osteotomies, bone windows, or fibrin glue, which are associated with donor pain and nonunion. Thus, for larger and cystic lesions, we report our experience using a modified low-flow arthroscopic sandwich technique consisting of autologous cancellous bone graft, followed by a viable cryopreserved cartilage fiber, cartilage allograft matrix putty.

Osteochondral lesions of the talus (OCLT) are complex injuries occurring often as a result of traumatic events and within active populations and affect return to activity, length of recovery, and long-term functionality of the ankle. Ankle sprains and ankle fractures account for a large percentage of articular cartilage injuries, upwards of 50% and 75%, respectively.<sup>1</sup> The unique anatomy of the talus coupled with its limited capacity for repair require early diagnosis and intervention. Treatment of OCLTs is further complicated by the forces transmitted through the ankle joint requiring appropriate fixation and post-operative rehabilitation.<sup>2</sup> The ideal treatment strategy is still debated; however, in the event of nonoptimal

management, the functional prognosis of the ankle can be severely impacted.<sup>3,4</sup> Appropriate management of complex osteochondral lesions of the talus remains difficult, and current surgical approaches have clear limitations and varied outcomes.

Accurate diagnosis of complex lesions requires a combination of careful history and physical examination, as well as use of appropriate imaging. Advanced imaging such as magnetic resonance imaging enables assessment of lesion location, size, and cartilage mechanical stability with a high degree of accuracy.<sup>5</sup> There are numerous patient reports and surgical techniques described that may be considered based on the size, stage, and chronicity of the lesion, as well as patient activity level. For smaller lesions (<10 mm) with subchondral cysts and intact overlying cartilage, retrograde drilling with autologous bone grafting is the frequently used approach.<sup>6</sup> Treatment options for larger OCLTs (>10 mm) modify the structure of the talus to counteract cystic remnants. Osteochondral autograft transplantation and osteochondral allograft transplantation replace defective cartilage with normal hyaline cartilage. However, these approaches require a longer recovery time, carry greater morbidity, and often fail to replicate the complex contour of the talus.<sup>7</sup> Options for larger OCLTs include autologous chondrocyte implantation (ACI) and matrix-associated ACI (MACI).<sup>8</sup> The biggest drawback is that these techniques require 2 stages, with multiple weeks between them to culture biopsied chondrocytes and only recreate a hyaline-like

From the Department of Orthopaedics, The Ohio State University Wexner Medical Center (D.J.W., K.D.M.) and The Ohio State University College of Medicine (H.H.S., A.G.F.S.), Columbus, OH, U.S.A.

The authors report the following potential conflict of interest or source of funding: K.M. is a paid consultant for Arthrex and ConMed. Full ICMJE author disclosure forms are available for this article online, as [supplementary material](#).

Received April 19, 2023; accepted July 7, 2023.

Address correspondence to Kevin Martin, D.O., Jameson Crane Sports Medicine Institute, 2835 Fred Taylor Rd, Columbus, OH 43202, U.S.A. E-mail: [Kevin.Martin@osumc.edu](mailto:Kevin.Martin@osumc.edu)

© 2023 THE AUTHORS. Published by Elsevier Inc. on behalf of the Arthroscopy Association of North America. This is an open access article under the CC BY-NC-ND license (<http://creativecommons.org/licenses/by-nc-nd/4.0/>).

2212-6287/23590

<https://doi.org/10.1016/j.eats.2023.07.002>

cartilage matrix. This adds to overall cost—a significant drawback of MACI and ACI relative to other OCLT treatment methods. Given the variability of patient outcomes, increased costs, and use of multistaged approaches, we suggest an alternative arthroscopic technique approach to treat large, complex osteochondral lesions.

For patients with symptomatic, larger osteochondral lesions or for those with poor response to nonoperative management, operative treatment is typically required. There are limited reports on the use of low-flow arthroscopy using a sandwich technique for the treatment of large osteochondral lesions of the talus. Thus, for larger and cystic lesions, we report our technique using a modified low-flow arthroscopic sandwich technique consisting of autologous cancellous bone graft, followed by a viable cryopreserved cartilage fiber, cartilage allograft matrix putty.

### Surgical Technique

Preoperative planning is necessary before execution of the procedure. Plain radiographs should be obtained to evaluate the osteochondral lesion. Obtaining preoperative imaging is additionally useful for evaluating healing response in subsequent follow-up visits. Advanced imaging in the form of computed tomography or magnetic resonance imaging is then obtained to better characterize the location and size of the lesion. Examples of plain radiographs and associated advanced imaging from patient cases are demonstrated in [Figure 1](#).

#### Positioning and Prepping

The patient can be positioned either supine or prone for completion of the procedure depending on the location of the osteochondral lesion on the talus. The following steps are performed for a standard supine ankle arthroscopy. The patient is transferred to the operative table in the supine position with both feet hanging off the end of the bed, and general anesthesia is induced. A well-padded tourniquet is then applied to the proximal thigh of the operative extremity. A safety strap is placed around the patient's waist, and a 4-inch strip of silk tape is applied around the contralateral leg to prevent movement of the leg during the procedure. A pre-prep using chlorhexidine soap and alcohol bath is performed. The operative extremity is then prepped and draped in standard sterile fashion. All the toes are wrapped together with Ioban (3M Corp, St. Paul, MN) to maintain strict sterility of the surgical field.

#### Diagnostic Arthroscopy

A surgical skin marker is then used to map out pertinent structures for anterior ankle arthroscopy. The anterior tibialis tendon is palpated by bringing the foot into dorsiflexion and using a thumb on either side of

the tendon to fully appreciate the width. The antero-medial viewing portal is then marked just medial to the tendon at the medial shoulder of the talus. A low-flow 1.9 mm mini arthroscope (NanoScope; Arthrex Inc, Naples FL) with a blunt plastic tip is inserted via a small stab incision using the nick-and-spread technique. A low-flow arthroscope is used to reduce fluid extravasation into the capsule and to mitigate any potential compartment pressurization. The lateral portal is created in a similar fashion under direct visualization with the scope. A 20-gauge spinal needle is used to verify the position of the lateral working portal, which is then created with the nick-and-spread technique. Next, a 3.5 mm shaver is introduced to perform thorough debridement of the medial, central, and lateral gutters of the ankle joint. A diagnostic arthroscopy of the anterior six zones of the talus is performed, and the osteochondral defect is identified as demonstrated in [Video 1](#). A simple 1-step noninvasive ankle distractor is applied for additional access.<sup>9</sup> The nonviable edges of the osteochondral lesion and cystic bone are then meticulously debrided with an arthroscopic curette, and the size of the lesion is measured during surgery ([Fig 2](#)).

#### Bone Graft Harvest

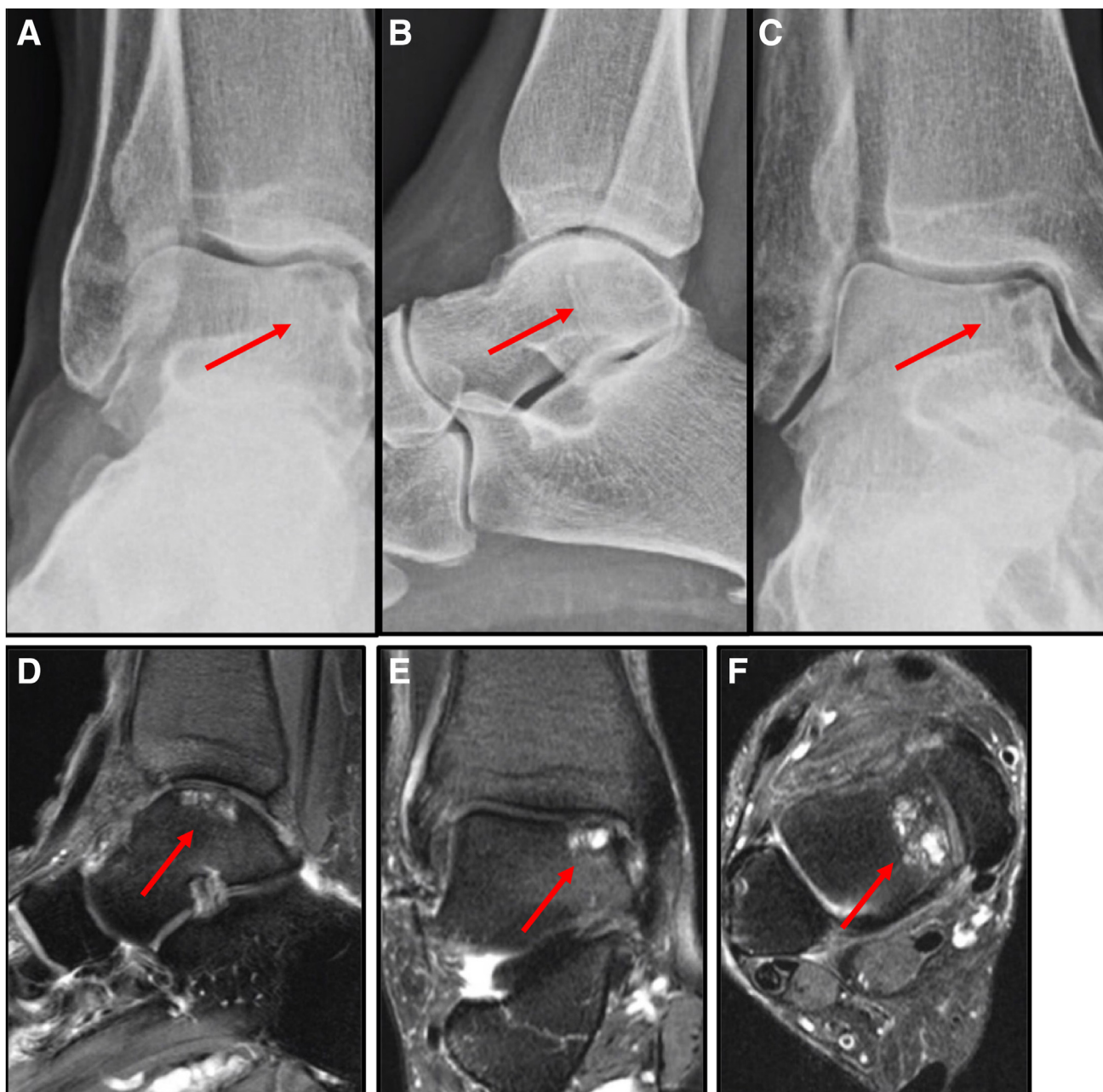
A small portal size incision on the lateral wall of the calcaneus is created using the nick-and-spread technique. The periosteum is then elevated, and a small disposable 6 mm core reamer is used to take a cylinder of cancellous bone. The bony graft is then thoroughly dried and placed into a modified (end cut off at a 45° angle) 1 mL syringe and subsequently arthroscopically placed directly in the recessed area of the osteochondral lesion.

#### Graft Placement

A Freer Elevator or the back side of a curette can be used to pack the graft firmly into the lesion, while keeping it recessed 2 to 3 mm below the surrounding cartilage rim. Maintaining a dry environment for the graft is critical. This can be performed by using suction and sterile cotton swabs repetitively to wick the remaining moisture out of the joint ([Fig 3](#)).

Then the viable cryopreserved allograft (CartiMax; Conmed Inc., Largo, FL) is manipulated into a putty, described further in [Video 1](#), and placed into a similar modified 1 mL syringe and introduced into the lesion via a dry arthroscopic delivery. Maintaining a dry environment is paramount as the allograft is spread over the osteochondral lesion to achieve an even fill and in keeping it level or slightly recessed below the articular surface. Contour the shoulder lesion for good fill on all sides under multiple visualization viewing portals. Unlike other cartilage matrix allografts, no fibrin glue is needed because of the adherent viable cells and putty consistency.

Traction is then removed. The portals are closed with a simple portal stitch with 3-0 nylon suture. A



**Fig 1.** (A) Anteroposterior and (B) lateral views of preoperative radiographs demonstrating the extent of the osteochondral lesion with cystic changes to the medial talar dome. (C) An oblique (mortise) view of the ankle in  $10^{\circ}$  to  $20^{\circ}$  of internal rotation that better visualizes the extent of the cystic osteochondral lesion of the medial talar dome extending throughout the articular surface. (D) Sagittal, (E) coronal, and (F) axial views represent the corresponding magnetic resonance images, further demonstrating an unstable cartilage flap with underlying cystic changes extending to the shoulder of the talus.

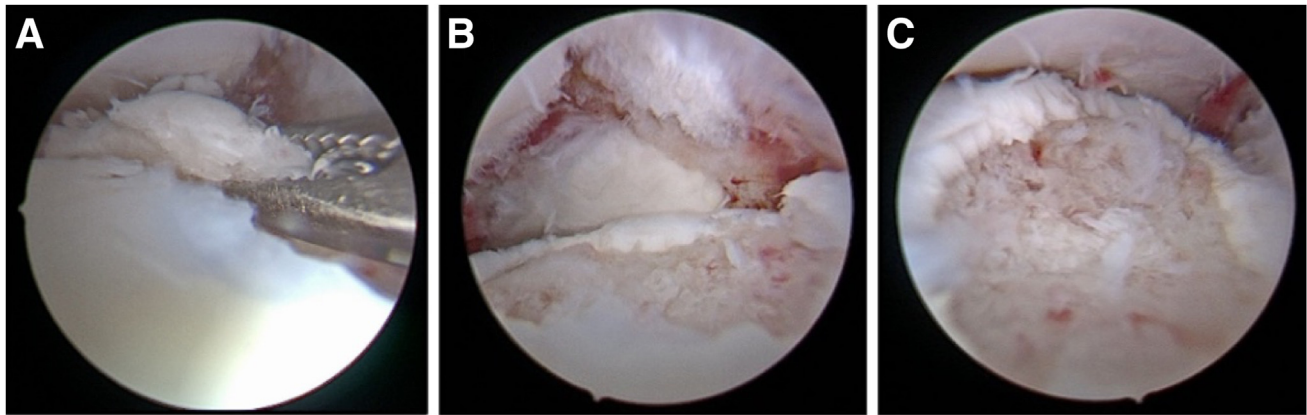
postoperative block using local anesthesia is achieved by injecting a combination of approximately 20 mL of ropivacaine and 20 mL of lidocaine. Xeroform is applied over the portal incisions followed by  $4 \times 4$  gauze and a soft compressive wrap and tall postoperative boot.

#### Postoperative Plan

The patient is to be nonweightbearing for 6 weeks and given aspirin 81 mg twice daily for 2 weeks for deep vein

thrombosis prophylaxis. We encourage a hands-free single crutch (iWalkFree, Mansfield, ON), because of found increased muscle recruitment and intensity compared to axillary crutches.<sup>10</sup> Progressive protected weightbearing in the postoperative boot begins at 6 weeks. The boot is discontinued between 10 to 12 weeks after surgery, a simple ankle lace-up brace is used for an additional 4 to 6 weeks as strength and balance improve. Daily vitamin D<sub>3</sub> supplementation is strongly encouraged for 6 months





**Fig 2.** Right supine arthroscopic images from the anterolateral portal show removal of the loose cartilage flap from the medial talar dome (A). Further evaluation under arthroscopic visualization is completed to quantify the extent of the lesion. (B) The lesion from the anteromedial portal and (C) early debridement of the osteochondral lesion.

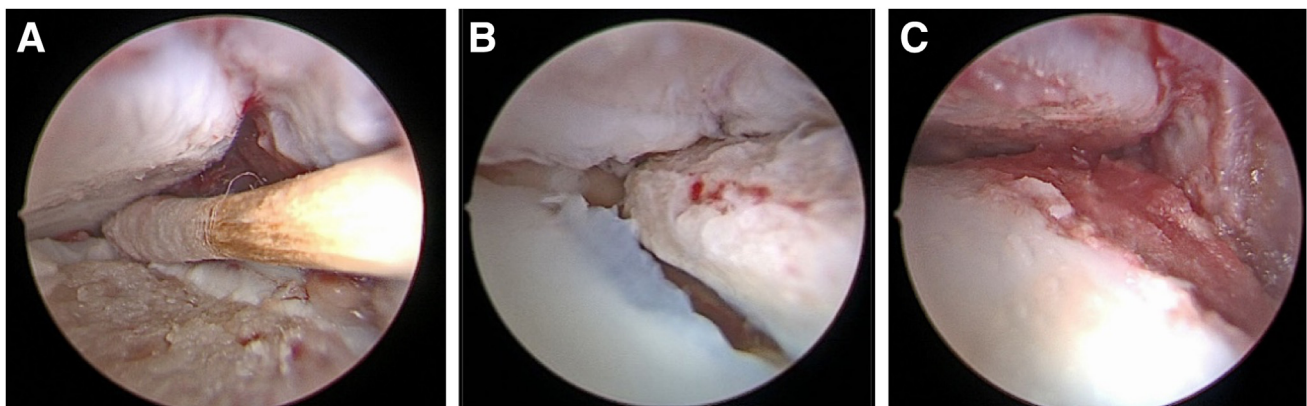
after surgery. We encourage early recumbent stationary biking and swimming in combination with blood flow restriction therapy. Running or impact activities are restricted for the first 6 to 9 months.

### Discussion

To the best of our knowledge, this is among the few techniques describing the use of low-flow arthroscopy in combination with a single-stage viable autograft/allograft matrix not requiring fibrin glue (Table 1). There is limited research describing the use of an arthroscopic approach to the sandwich technique for the management of large OCLTs. For lesions failing conservative treatment, consensus on the appropriate surgical technique is unclear. In advanced larger osteochondral lesions, a sophisticated reconstruction is often needed to maintain the articular surface of the talus.<sup>11,12</sup> We believe that the described low-flow arthroscopic, autograft/allograft “sandwich” technique is a safe and effective approach with optimal joint restoration and high-quality patient outcomes.

Our multifaceted arthroscopic technique starts with a low-flow mini arthroscope, which minimizes fluid extravasation while providing enhanced magnified high-definition visualization of the lesion. Direct visualization of the defect allows for adequate debridement of the lesion, resection of unstable cartilage, cystic bone, and improved precision of defect repair.<sup>13</sup> Unlike osteochondral autograft transplantations and ACI/MACI, which require an osteotomy to restore the cystic defect, our technique provides direct arthroscopic autograft impaction grafting. The morbidity of an osteotomy and soft-tissue manipulation in combination with the potential for chronic knee (donor site) pain can limit early functional outcomes.<sup>14</sup> The arthroscopic sandwich technique reduces morbidity, cost, and complexity of implantation as compared to a 2-staged ACI.

Although management of large uncontained cystic OCLTs remains a very challenging problem, a single-stage localized cancellous autograft simplifies the bony defect.<sup>15</sup> Calcaneus autograft harvested with a



**Fig 3.** Right supine arthroscopic images from the anterolateral portal showing lesion preparation, using a cotton tip applicator to dry the area (A), arthroscopic delivery of the cartilage allograft via a modified 1 mL syringe into the lesion through the anteromedial portal (B), and the allograft covering the lesion with complete fill and contouring of the shoulder (C).

**Table 1.** Technical Pearls and Pitfalls of an Arthroscopic Sandwich Technique Approach for Surgical Repair of Osteochondral Lesions of the Talus With CartiMax

Pearls
Noninvasive distraction with Trimano (Arthrex Inc., Naples, FL)
1 mL syringe cut at 45° angle for delivery
Mini incision for bone graft from calcaneus, disposable harvester
Maintain strict dry environment with sterile cotton swabs
Do not overfill lesion with cancellous bone graft—make sure it is recessed 2-3 mm for the allograft cartilage cap
Pitfalls
Prolonged arthroscopy time leading to a saturated joint
Debride all cystic nonviable bone before grafting
Overfilling the lesion may potentially lead to overgrowth and impingement

disposable cannulated reamer minimizes thermal osteonecrosis while maximizing volume and providing multipotent mesenchymal stem cells. The autograft fills the void and provides osteoconductive, osteoinductive, and osteogenic properties, which creates a highly favorable interface for viable allograft. The putty-like consistency of the viable allograft naturally adheres to the donor site, eliminating the need for fibrin glue, which can lower in vitro proliferation and migration of chondrocytes.<sup>16</sup> Eliminating fibrin glue removes a cellular barrier, additional cost, and surgeon frustration given the complexity of applying a thin, even layer and its associated drying time.

In conclusion, using a low-flow arthroscopic autograft/allograft “sandwich” technique can allow for simplification of a complex issue while addressing the multifaceted problem. Our technique eliminates the need for multiple surgeries, osteotomies, fibrin glue and extensive soft-tissue disruptions while maximizing cellular ingrowth potentials and simplicity.

## References

1. Wodicka R, Ferkel E, Ferkel R. Osteochondral lesions of the ankle. *Foot Ankle Int* 2016;37:1023-1034.
2. O’Loughlin P, Heyworth BE, Kennedy JG. Current concepts in the diagnosis and treatment of osteochondral lesions of the ankle. *Am J Sports Med* 2010;38:392-404.
3. Barbier O, Amouyel T, de l’Escalopier N, et al. Osteochondral lesion of the talus: What are we talking about? *Orthop Traumatol Surg Res* 2021;107(8S), 103068.
4. Dahmen J, Lambers KTA, Reilingh ML, van Bergen CJA, Stufkens SAS, Kerkhoffs GMMJ. No superior treatment for primary osteochondral defects of the talus. *Knee Surg Sports Traumatol Arthrosc* 2018;26:2142-2157.
5. Mintz DN, Tashjian GS, Connell DA, Deland JT, O’Malley M, Potter HG. Osteochondral lesions of the talus: A new magnetic resonance grading system with arthroscopic correlation. *Arthroscopy* 2003;19:353-359.
6. Anders S, Lechler P, Rackl W, Grifka J, Schaumburger J. Fluoroscopy-guided retrograde core drilling and cancellous bone grafting in osteochondral defects of the talus. *Int Orthop* 2012;36:1635-1640.
7. Nam EK, Ferkel RD, Applegate GR. Autologous chondrocyte implantation of the ankle: A 2- to 5-year follow-up. *Am J Sports Med* 2009;37:274-284.
8. Anders S, Goetz J, Schubert T, Grifka J, Schaumburger J. Treatment of deep articular talus lesions by matrix associated autologous chondrocyte implantation—Results at five years. *Int Orthop* 2012;36:2279-2285.
9. Unangst A, Martin KD. Simple 1-step ankle arthroscopy distraction. *Arthrosc Tech* 2015;4(6):e873-e876.
10. Martin KD, Unangst AM, Huh J, Chisholm J. Patient preference and physical demand for hands-free single crutch vs standard axillary crutches in foot and ankle patients. *Foot Ankle Int* 2019;40:1203-1208.
11. Sadlik B, Gobbi A, Pałka K, Herman K. One-stage treatment for osteochondral lesion of the talus. In: Canata GL, d’Hooghe P, Hunt KJ, Kerkhoffs GMMJ, Longo UG, eds. *Sports Injuries of the Foot and Ankle: A Focus on Advanced Surgical Techniques*. Berlin: Springer, 2019;149-158.
12. Sadlik B, Kolodziej L, Blasiak A, Szymczak M, Warchal B. Biological reconstruction of large osteochondral lesions of the talar dome with a modified “sandwich” technique—Midterm results. *Foot Ankle Surg* 2017;23:290-295.
13. Giannini S, Vannini F. Operative treatment of osteochondral lesions of the talar dome: Current concepts review. *Foot Ankle Int* 2004;25:168-175.
14. Andrade R, Vasta S, Pereira R, et al. Knee donor-site morbidity after mosaicplasty—A systematic review. *J Exp Orthop* 2016;3:31.
15. Hurley ET, Stewart SK, Kennedy JG, Strauss EJ, Calder JDF, Ramasamy A. Current management strategies for osteochondral lesions of the talus. *Bone Joint J* 2021;103-B 2:207-212.
16. Migliorini F, Prinz J, Maffulli N, et al. Fibrin glue does not assist migration and proliferation of chondrocytes in collagenic membranes: An in vitro study. *J Orthop Surg Res* 2022;17:311.