

Utilization of a Viable Human Amnion Membrane Allograft in Elderly Patients With Chronic Lower Extremity Wounds of Various Etiologies

Matthew Regulski, DPM

ABSTRACT

Introduction. Chronic nonhealing wounds are a growing health care problem in the United States, afflicting more than 6.5 million patients annually. In particular, diseases that compromise skin integrity and impair normal wound healing processes, such as diabetes and peripheral vascular diseases, are becoming more common in the aging population and leading to ever-increasing incidence of these chronic nonhealing wounds. **Objective.** The aim of this study is to evaluate a viable human amnion membrane allograft (vHAMA) for the treatment of chronic nonhealing wounds in elderly patients (aged > 65 years) with multiple comorbidities. **Materials and Methods.** Four patients (age range, 69–85 years) with 5 chronic wounds of varying etiologies and sizes (2 traumatic wounds, 2 diabetic foot ulcers, and 1 venous leg ulcer) that persisted for at least 4 weeks and failed previous treatment with standard of care were included in this study. Comorbidities included diabetes mellitus, obesity, polymyalgia rheumatica, lymphedema, peripheral vascular disease, steroid use, and neuropathy. All patients received vHAMA once weekly or as deemed appropriate. **Results.** All patients reached complete wound closure with no complications or adverse events. Mean time to closure was 4.8 weeks (range, 2–8 weeks) with an average of 4.2 grafts (range, 1–8). There was no wound recurrence. **Conclusions.** Successful closure of wounds indicates the use of vHAMA may be beneficial for treatment of chronic wounds in elderly patients with comorbidities.

KEY WORDS

chronic, viable amnion, diabetic foot ulcer, lower extremity wound, venous leg ulcer, allograft

INDEX

Wounds 2018;30(3):E36–E40.

Chronic nonhealing wounds are a growing health care problem in the United States, afflicting more than 6.5 million patients annually.¹ In particular, comorbidities and diseases that compromise skin integrity and impair normal wound healing processes, such as diabetes and peripheral vascular diseases, are becoming more common in the aging population and leading to ever-increasing incidence of these chronic nonhealing wounds.² At the same time, age is a known systemic factor that causes delayed wound healing through changes in skin characteristics and an altered wound healing process, partially mediated by keratinocytes and epithelial

cells undergoing cell senescence, which are cell proliferation-arrested yet can continue to secrete proinflammatory cytokines, chemokines, growth factors, and proteases that hinder the progression of healing.^{3–5}

Viable human amnion membrane allograft (vHAMA; AmnioBand Viable Membrane; MTF Biologics, Edison, NJ) is a new, commercially available, cryopreserved viable human amnion membrane that retains the native matrix proteins, growth factors, cytokines, and endogenous living cells within the tissue matrix throughout processing.^{6,7} These components of amnion are thought to work synergistically to provide its

function in development as a protective barrier with anti-inflammatory and immunomodulatory properties that also are beneficial for the progression of wound healing that may be delayed in part due to patient age-related factors.^{8–14}

The aim of this case series is to evaluate a vHAMA in conjunction with standard of care for the treatment of chronic nonhealing wounds in elderly patients (aged > 65 years) with multiple comorbidities.

MATERIALS AND METHODS

Four elderly patients with 5 chronic wounds of varying etiologies and sizes (2 traumatic wounds, 2 diabetic foot ulcers

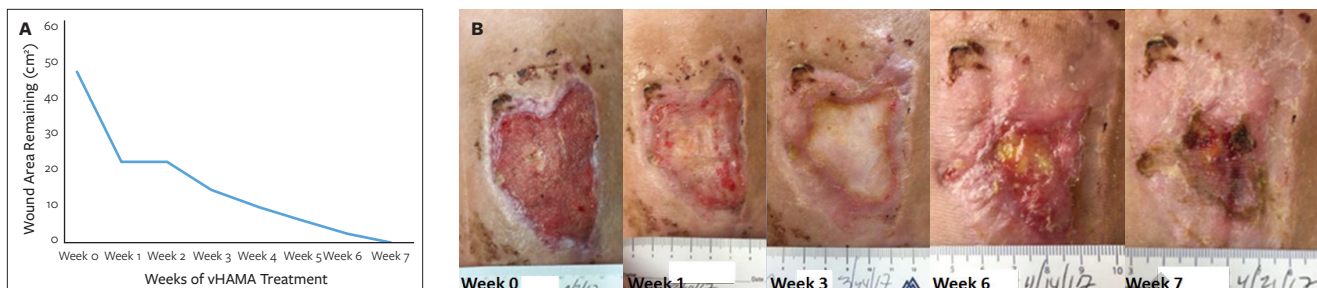


Figure 1. A 69-year-old obese woman presented with nonhealing traumatic wounds of the left leg that had been open for 9 weeks. (A) Wound progression from before initial viable human amnion membrane allograft (vHAMA) treatment to complete wound closure after 7 weeks (6 total applications); and (B) healing trajectory of wound from size of 48.02 cm² prior to initial vHAMA treatment to closure after 7 weeks of vHAMA treatment.

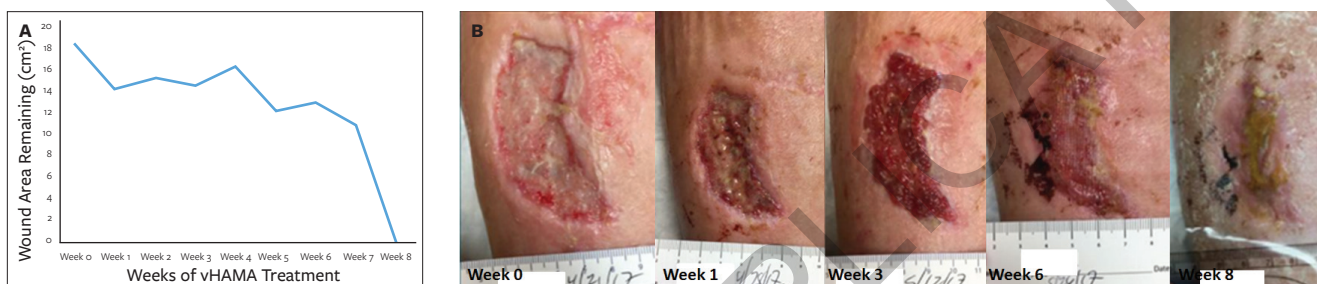

Figure 2. A 69-year-old obese woman presented with nonhealing traumatic wounds of the right leg that had been open for 8 weeks. (A) Wound progression from before initial viable human amnion membrane allograft (vHAMA) treatment to complete wound closure after 8 weeks of vHAMA treatment (7 total applications); and (B) healing trajectory of wound from size of 18.47 cm² prior to initial vHAMA treatment to closure after 8 weeks of vHAMA treatment.

[DFUs], and 1 venous leg ulcer [VLU] that had persisted for at least 4 weeks and failed previous treatment with standard of care were included in this study; average patient age was 76 years (range, 69–85 years). Comorbidities included diabetes mellitus, obesity, polymyalgia rheumatica, lymphedema, peripheral vascular disease, steroid use, and neuropathy. All patients were treated at the Ocean County Foot & Ankle Surgical Associates, P.C. (Forked River, NJ, and Toms River, NJ).

Wound surface area was measured via a smartphone-based wound measurement app (Tissue Analytics, Inc, Baltimore MD). All patients received vHAMA once weekly or as deemed appropriate by the author in addition to standard of care (ie, sharp debridement, moist wound balancing, and offloading for DFU; VLU included multilayer compression with sharp debridement and moist wound balancing). At each visit, sharp debridement was performed on the wound as appropriate.

The vHAMA graft was thawed and rinsed per product instructions for use and applied either directly from the backing to the wound or transferred first to a nonadherent primary dressing (ADAPTIC TOUCH Non-Adhering Silicone Dressing; Systagenix, an Acelyty Company, San Antonio, TX) and then applied to the wound. The graft was adjusted to ensure intimate contact with the wound bed and margins. Any excess graft was folded back over the graft such that the graft did not extend past and only slightly overlapped the wound margins. After graft application, a nonadherent primary dressing was placed over the wound and then covered with a secondary dressing and/or multilayer compression wrap as needed. In some cases, where the patient required use of the foot, an appropriate offloading device was provided.

RESULTS

All patients in this case series reached complete wound closure with no

complications or adverse events. Mean time to closure was 4.8 weeks (range, 2–8 weeks) with an average of 4.2 grafts applied (range, 1–8). Average size of the wounds was 13.65 cm² (range, 0.05 cm²–48.02 cm²).

Case 1

A 69-year-old obese woman with a history of deep vein thrombosis, pulmonary embolism, and polymyalgia rheumatica presented with nonhealing traumatic wounds of the left leg (anterior surface, open for 9 weeks; **Figure 1**) and the right leg (anterior surface, open for 8 weeks; **Figure 2**) that were complicated by lymphedema and steroid use (5 mg of prednisone for polymyalgia rheumatica > 10 years).

Prior to the initial vHAMA graft application, her left leg wound had an area of 48.02 cm² with a depth of 0.40 cm (**Figure 1B**), and her right leg wound had an area of 18.47 cm² with a depth of 0.20 cm (**Figure 2B**). A vHAMA graft was placed on the wounds and covered with

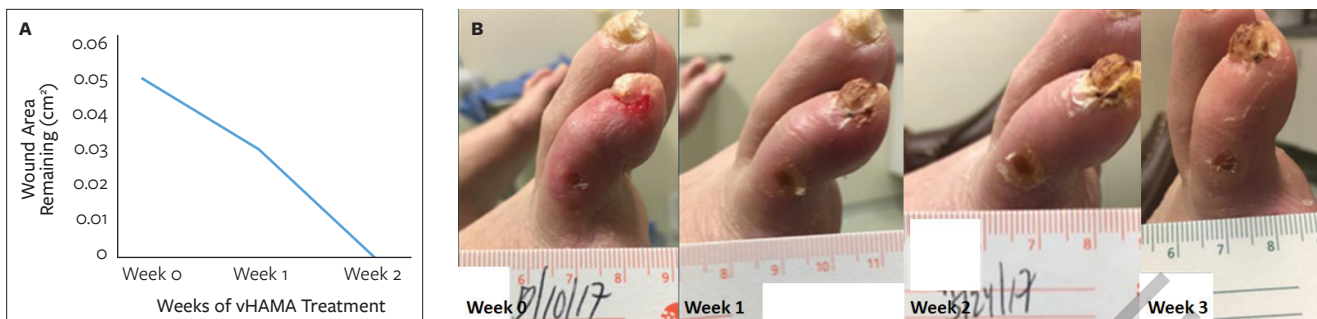

Figure 3. An 80-year-old man presented with a diabetic foot ulcer of the right third toe reaching down through fascia over tendon/bone that had been open for 4 weeks. (A) Wound progression from before initial viable human amnion membrane allograft (vHAMA) treatment to complete wound closure after 2 weeks of vHAMA treatment (1 total application). A follow-up visit at 3 weeks verified that the wound remained closed; and (B) healing trajectory of wound from initial size of 0.05 cm² to closure after 2 weeks of vHAMA treatment.

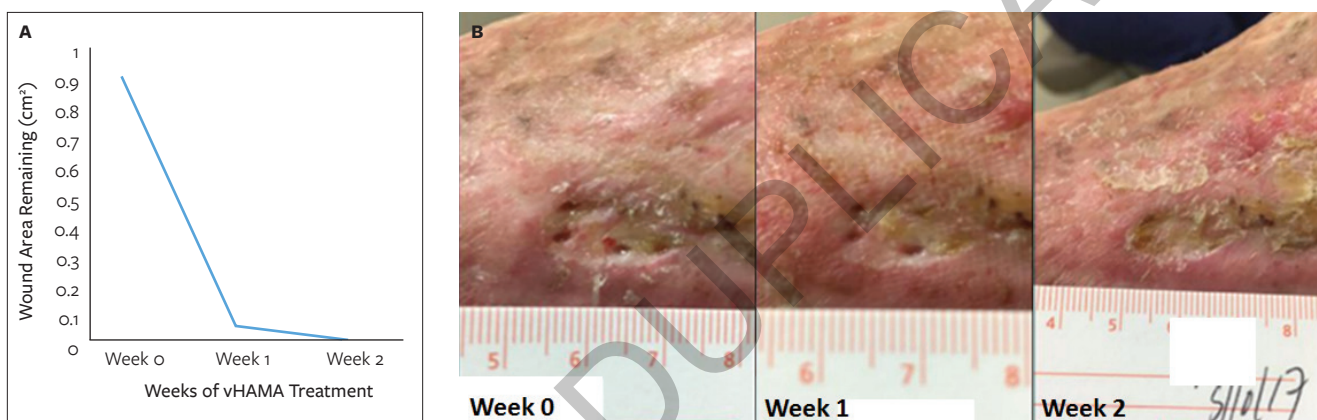


Figure 4. An 85-year-old woman presented with a diabetic foot ulcer on the superolateral surface of the left foot that had been open for 13 months. (A) Wound progression from before initial viable human amnion membrane allograft (vHAMA) treatment to complete wound closure after 2 weeks of vHAMA treatment (2 total applications); and (B) healing trajectory of wound from initial size of 0.91 cm² to closure after 2 weeks of vHAMA treatment.

a nonadherent primary dressing and multilayer compression wrap. The patient noted no pain at the second visit 1 week later (Figures 1B, 2B) and received a total of 6 applications of vHAMA over 7 weeks on her left leg (Figure 1B) and 8 applications of vHAMA over 8 weeks on her right leg (Figure 2B), resulting in successful closure of both wounds.

Case 2

An 80-year-old man with type 2 diabetes and a history of poor balance due to neuropathy and previous amputation of the right fourth and fifth toes for gangrene and hammertoe of the right third toe presented with a DFU (Figure 3) reaching down through fascia over tendon/bone on the right third toe (open for 4 weeks) with a starting wound

area of 0.05 cm² and a depth of 0.30 cm (Figure 3B).

A vHAMA graft was placed on the wound and covered with a nonadherent primary dressing, and he also was provided with a CAM walker boot. He received a total of 1 application of vHAMA over 2 weeks, resulting in closure of the wound. A follow-up visit at 3 weeks confirmed that the wound remained closed (Figure 3).

Case 3

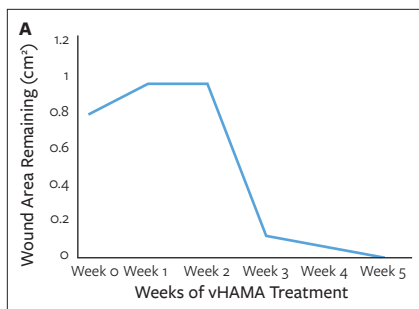
An 85-year-old woman with type 2 diabetes and a history of venous disease and wearing a compression sock to control venous reflux and edema presented with a DFU on the superolateral surface of the left foot (open for 13 months) with a starting area of 0.91 cm² and a depth

of 0.20 cm and very fibrotic surrounding tissue (Figure 4). Blood flow was acceptable with some calcifications.

A vHAMA graft was placed on the wound and covered with a nonadherent primary dressing and multilayer compression wrap. She reached wound closure after a total of 2 applications of vHAMA over 2 weeks (Figure 4).

Case 4

A 70-year-old man with type 2 diabetes and a history of deep vein thrombosis, lymphedema, and recurrent VLU presented with a VLU on the left inferomedial ankle (open 9 weeks) with a starting size of 0.80 cm² and depth of 0.50 cm (Figure 5). Satisfactory blood flow was confirmed prior to initial vHAMA treatment.



The results of this case series of 4 elderly patients (average age, 76 years) with a total of 5 chronic nonhealing wounds (2 traumatic wounds, 2 diabetic foot ulcers, 1 venous leg ulcer) that were treated with a viable human amnion membrane allograft demonstrate the need for future prospective randomized studies on chronic wounds to further prove the efficacy of utilizing this type of allograft in comparison to other existing treatment options.

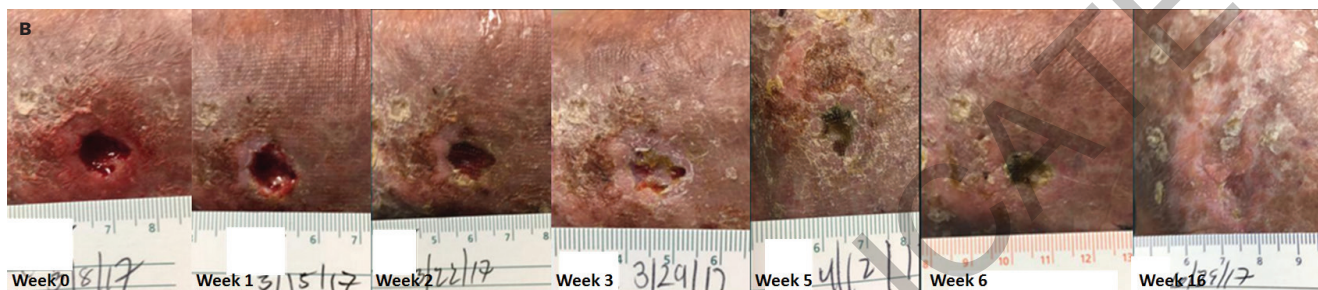


Figure 5. A 70-year-old man presented with a venous leg ulcer on the left inferomedial ankle that had been open for 9 weeks. (A) Wound progression from before initial viable human amnion membrane allograft (vHAMA) treatment to complete wound closure after 5 weeks of vHAMA treatment (4 total applications). Follow-up visits at 6 and 16 weeks verified that the wound had remained closed; and (B) healing trajectory of wound from initial size of 0.80 cm to closure after 7 weeks of vHAMA treatment.

A vHAMA graft was placed on the wound and covered with a nonadherent primary dressing and multilayer compression wrap. He received a total of 4 applications of vHAMA over 5 weeks resulting in closure of the wound. The wound had remained closed at the 6-week follow-up visit; another follow-up at 16 weeks showed no recurrence of the ulcer (**Figure 5**).

DISCUSSION

Placenta membranes have been used since the early 1900s as biological dressings for wounds.¹⁵⁻¹⁷ Since then, these tissues have been characterized in the literature as a collagen-rich extracellular matrix, containing a plethora of growth factors, cytokines, and viable epithelial cells, fibroblasts, and mesenchymal stem cells (MSCs).^{9,10,18-22} In particular, MSCs are potent contributors to all phases of the wound healing process with their ability to home into wounds followed by their immunomodulatory capacity, to recruit other host cells, and to produce a plethora of growth factors and matrix proteins needed for wound healing.⁹⁻¹¹

These capabilities signify that MSCs and other cells are critical mediators of all phases of the wound healing process through cell signaling/recruitment, growth factor and cytokine secretion, proliferation, and ultimate remodeling of the wound. Thus, by utilizing a placental allograft with multiple viable cell populations, including MSCs, this provides the cells an opportunity to continue producing and making available the proteins necessary for wound repair and regeneration dictated by the environment in the wound. These robust, young cells are not compromised by age or by disease (eg, diabetes), which can cause premature aging and senescence of cells and diminish their function, homing ability, and proliferative capability.^{3,5} Introducing these cells into a chronic wound environment can help bolster wound healing and regeneration activities beyond the capabilities of compromised, senescent host cells alone; therefore, it resurrects a regenerative process that is skewed in elderly patients with chronic, recalcitrant wounds.³⁻⁵

LIMITATIONS

The current case series shows promise in the use of vHAMA for the treatment of chronic wounds in elderly patients. As a case series, the small sample size and absence of a control group limits the ability to draw conclusions about the efficacy of vHAMA treatment for chronic wounds.

CONCLUSIONS

In the geriatric population, the increased incidence of chronic wounds coupled with a decreased capacity for wound healing presents a challenging problem for the wound care provider. Successful closure of chronic wounds with several different etiologies (traumatic wound, DFU, and VLU) suggests the use of vHAMA allografts may be beneficial for the treatment of various chronic wounds in elderly patients with multiple comorbidities. These results indicate that prospective randomized studies in chronic wounds are warranted to further validate the efficacy of this treatment compared with existing treatment options. **W**

ACKNOWLEDGMENTS

Affiliations: Medical Director, Wound Care Institute of Ocean County, Toms River, NJ; and Partner, Ocean County Foot and Ankle Surgical Associates, Toms River, NJ

Correspondence: Ocean County Foot and Ankle Surgical Associates, 54 Bey Lea Road, Toms River, NJ 08753; mregulski@comcast.net

Disclosure: This study was funded by MTF Biologics (Edison, NJ). This paper was presented as a poster at the Symposium on Advanced Wound Care Fall 2017 in Las Vegas, NV.

REFERENCES

1. Sen CK, Gordillo GM, Roy S, et al. Human skin wounds: a major and snowballing threat to public health and the economy. *Wound Repair Regen.* 2009;17(6):763–771.
2. Gist S, Tio-Matos I, Falzgraf S, Cameron S, Beebe M. Wound care in the geriatric client [published online ahead of print June 9, 2009]. *Clin Interv Aging.* 2009;4:269–287.
3. Guo S, DiPietro LA. Factors affecting wound healing [published online ahead of print February 5, 2010]. *J Dent Res.* 2010;89(3):219–229.
4. Gosain A, DiPietro LA. Aging and wound healing [published online ahead of print February 17, 2004]. *World J Surg.* 2004;28(3):321–326.
5. Regulski MJ. Cellular senescence: what, why, and how. *Wounds.* 2017;29(6):168–174.
6. Dasgupta A, Wu K, Madans A, Chnari E, Jacobs M. Aseptically Processed Cryopreserved Amnion Membrane Preserves Essential Bioactive Components that Support the Progression of the Wound Healing Cascade. Poster presented at: Symposium on Advanced Wound Care Spring; April 29–May 3, 2015; San Antonio, TX.
7. Wu K, Dasgupta A, Madans A, Phipps A, Chnari E. Aseptically Processed Cryopreserved Amnion Tissue Effectively Preserves Endogenous Adherent Cells with Multipotential Characteristics and Capability. Poster presented at: Symposium on Advanced Wound Care Spring; April 5–9, 2017; San Diego, CA.
8. Niknejad H, Peirovi H, Jorjani M, Ahmadiani A, Ghanavi J, Seifalian AM. Properties of the amniotic membrane for potential use in tissue engineering. *Eur Cell Mater.* 2008;15:88–99.
9. Hocking AM. The role of chemokines in mesenchymal stem cell homing to wounds. *Adv Wound Care (New Rochelle).* 2015;4(11):623–630.
10. Maxson S, Lopez EA, Yoo D, Danilkovitch-Miagkova A, Leroux MA. Concise review: role of mesenchymal stem cells in wound repair. *Stem Cells Transl Med.* 2012;1(2):142–149.
11. Regulski MJ. Mesenchymal stem cells: “guardians of inflammation”. *Wounds.* 2017;29(1):20–27.
12. Steed DL, Trumpower C, Duffy D, et al. Amnion-derived cellular cytokine solution: a physiological combination of cytokines for wound healing. *Eplasty.* 2008;8:e18.
13. Gupta A, Kedige SD, Jain K. Amnion and chorion membranes: potential stem cell reservoir with wide applications in periodontics [published online ahead of print December 6, 2015]. *Int J Biomater.* 2015;2015:274082. doi: 10.1155/2015/274082.
14. Werner S, Grose R. Regulation of wound healing by growth factors and cytokines. *Physiol Rev.* 2003;83(3):835–870.
15. Davis JW. Skin transplantation with a review of 550 cases at the Johns Hopkins Hospital. *Johns Hopkins Med J.* 1910;15:307–396.
16. Sabella N. Use of fetal membranes in skin grafting. *Medical Rec (NY).* 1913;83(11):478–480.
17. Stern M. Grafting of preserved amniotic membrane to burned and ulcerated surfaces, substituting skin grafts. *JAMA.* 1913;60(13):973–974.
18. Bryant-Greenwood GD. The extracellular matrix of the human fetal membranes: structure and function. *Placenta.* 1998;19(1):1–11.
19. Wolbank S, Hildner F, Redl H, van Griensven M, Gabriel C, Hennerbichler S. Impact of human amniotic membrane preparation on release of angiogenic factors. *J Tissue Eng Regen Med.* 2009;3(8):651–654.
20. Koizumi NJ, Inatomi TJ, Sotozono CJ, Fullwood NJ, Quantock AJ, Kinoshita S. Growth factor mRNA and protein in preserved human amniotic membrane. *Curr Eye Res.* 2000;20(3):173–177.
21. Miki T, Lehmann T, Cai H, Stolz DB, Strom SC. Stem cell characteristics of amniotic epithelial cells [published online ahead of print August 4, 2005]. *Stem Cells.* 2005;23(10):1549–1559.
22. Lindenmair A, Hatlapatka T, Kollwig G, et al. Mesenchymal stem or stromal cells from amnion and umbilical cord tissue and their potential for clinical applications. *Cells.* 2012;1(4):1061–1088.