

# Role of Fresh Frozen Cartilage in Revision Rhinoplasty

Raja Mohan, M.D.  
R. Raja Shanmuga Krishnan,  
M.R.C.S.  
Rod J. Rohrich, M.D.

Dallas, Texas; and Coimbatore, India



**Background:** Correction of secondary nasal deformities frequently requires cartilage to build the framework of the nose. Traditionally, autologous costal cartilage has been used because of the paucity of the septal cartilage. Because of associated donor-site complications and increased operating time, irradiated allografts have been used. These grafts have a higher rate of resorption and infection. Thus, the authors have used fresh frozen, nonirradiated, cadaveric rib cartilage as donor cartilage to avoid these shortcomings, and they present their early experience.

**Methods:** The operative data of 50 patients who underwent secondary rhinoplasty performed by the senior author between 2014 and 2017 were analyzed. The outcomes of the rhinoplasty were evaluated by preoperative and postoperative photographs by four blinded plastic surgeons, and the results were tabulated using the Independent Rhinoplasty Outcome Score.

**Results:** Fifty patients were followed up over an average period of 3.35 months (range, 1 to 18 months). There was only one complication (infection, 2 percent), which did not need revision surgery. There was no warping or extrusion in this cohort.

**Conclusions:** The authors believe that fresh frozen, nonirradiated cartilage allografts are an evolving source of donor cartilage grafts for revision rhinoplasty because they are associated with lower complication rates. However, further long-term studies with an increased sample size are necessary to prove that fresh frozen cartilage grafts are better than other sources. (*Plast. Reconstr. Surg.* 144: 614, 2019.)

**CLINICAL QUESTION/LEVEL OF EVIDENCE:** Therapeutic, IV.

Revision rhinoplasty is a technically challenging procedure, and numerous studies have reported a 3.3 to 15.2 percent incidence of postoperative nasal deformities after primary rhinoplasty requiring a revision.<sup>1-3</sup> Common causes of nasal deformities requiring revision rhinoplasty include overresection of cartilage, residual dorsal hump, pollybeak deformity, and tip asymmetries.<sup>4</sup> Potential dead space and the resulting soft-tissue contraction results in loss of framework and cicatrization of the internal and external nasal valves, which can lead to nasal airway obstruction and the need for revision rhinoplasty.<sup>5</sup>

Although septal cartilage is ideal for cartilage grafts in rhinoplasty, it is often unavailable or in limited quantity in a revision rhinoplasty. Revision

rhinoplasty usually requires the use of extra-anatomical cartilage grafts.<sup>6</sup> An ideal cartilage graft should be inexpensive and readily available without any donor-site morbidity. It should not be complicated by resorption, infection, or warping.<sup>7</sup> When performing revision rhinoplasty, in situ autologous costal cartilage is commonly used.<sup>8</sup>

**Disclosure:** Dr. Rohrich receives instrument royalties from Eriem Surgical, Inc., and book royalties from Thieme Medical Publishing. He is a clinical and research study expert for Allergan, Inc., Galderma, and MTF Biologics, and the owner of Medical Seminars of Texas, LLC. No funding was received for this article. The remaining authors have no financial interests to disclose.

Related digital media are available in the full-text version of the article on [www.PRSJournal.com](http://www.PRSJournal.com).

From the Dallas Plastic Surgery Institute and Ganga Hospital.

Received for publication June 17, 2018; accepted October 31, 2018.

Copyright © 2019 by the American Society of Plastic Surgeons

DOI: 10.1097/PRS.0000000000005996

Other donor sites such as the concha usually do not have sufficient cartilage to be used as graft material (Table 1). The rib donor site is associated with many potential drawbacks, including prolonged postoperative pain, hypertrophic scarring, and pneumothorax.<sup>7</sup> The additional operating time in harvesting costal cartilage grafts adds to the overall cost of the procedure.<sup>9</sup>

Initial attempts to overcome these shortcomings with irradiated cartilage allografts were complicated by relatively higher resorption and infection rates.<sup>10,11</sup> The advent of a novel cadaveric, nonirradiated allograft that is processed and created using high-quality sterility standards could supplant the use of autologous or irradiated cartilage. It provides an avenue for an unlimited amount of different types of cartilage graft for use in complex revisionary rhinoplasties. The Musculoskeletal Transplant Foundation (Edison, N.J.) has provided an off-the-shelf option for extra-anatomical cartilage. Using a unique sterilization process, the Musculoskeletal Transplant Foundation produces a cadaveric rib allograft suitable for use in rhinoplasty. This fresh frozen cadaveric rib allograft has become a potential option because it avoids donor-site morbidity, is readily available, and each graft has different characteristics (i.e., pliability, strength).<sup>12</sup> In this study, we present the preliminary outcomes of revision rhinoplasty using this evolving source of graft material.

## PATIENTS AND METHODS

The study evaluated 50 patients (12 male patients and 38 female patients) who underwent revision rhinoplasty using fresh frozen allograft cartilage material produced by the Musculoskeletal Transplant Foundation. The procedures were performed at the Dallas Plastic Surgery Institute (Dallas, Texas) from 2014 to 2017 by the senior author (R.J.R.). Data from these patients' charts were analyzed in a retrospective manner. All patients were followed up for at least 1 month.

**Table 1. Comparison of Autologous Grafts**

Characteristic	Septal	Costal
Amount	++	+++
Donor-site morbidity	--	++
Warping	-	+
Ease of harvest	++	-
Structural support	+	++
Scarring	---	++
Operative time	-	++
Ease of carving	++	+

+, increased; -, decreased.

Retrospective reviews of medical records and photographic analysis were performed.

The study protocol was approved by the Western Institutional Review Board, and the study was performed according to the guidelines in the Declaration of Helsinki. Written informed consent was obtained from all patients whose photographs are presented in this article.

Fresh frozen cartilage grafts are harvested from donors using strict donor screening criteria. The donors are younger than 55 years, test negative for human immunodeficiency virus and hepatitis B and C, and do not have sepsis or active malignancy. The costal cartilages are harvested from the seventh to the ninth ribs, aseptically packed, and kept frozen. The tissue is first débrided of soft-tissue attachments and trimmed to an appropriate size. The cartilages are treated with a light surfactant to remove the blood, lipid, and cellular components from the donated tissue. After the initial cleansing step, the tissue is decontaminated using an antibiotic solution to remove any pathogenic contaminants from the tissue. The cartilage is rinsed and packaged under strict aseptic conditions, and sampled for final sterility, a process in which representative samples from each lot of tissue must test negative for microbes before distribution. Costal cartilage tissue is stored in a sealed sterile barrier under frozen conditions (-40° to -80°C). Cartilage tissue is shipped on dry ice to maintain temperature conditions while in transit, before implantation. Once thawed, the costal cartilage segments and sheets are ready for implantation.<sup>13</sup>

Fresh frozen costal cartilage was used primarily for the following grafts: dorsal onlay graft, spreader graft, columellar strut, intratip graft, alar contour graft, and septal extension graft. [See **Video 1 (online)**, which demonstrates an alar contour graft. A subcutaneous pocket is dissected precisely for placement of an alar contour graft. The graft is placed on the caudal border of the alar margin, and we recommend using fresh frozen allograft from a younger specimen. See **Video 2 (online)**, which demonstrates a tip graft. The tip graft made from fresh frozen allograft shown in this video is shaped like a tombstone and sutured into place using absorbable suture to refine and soften the contours of the nasal tip complex. This technique is performed after tip supporting sutures are placed. See **Video 3 (online)**, which demonstrates a septal extension graft. The septal extension graft is secured to the caudal and anterior portions of the septum using mattress sutures. Septal extension grafting is a powerful technique

to help control tip projection and rotation. See **Video 4 (online)**, which demonstrates a spreader graft and columellar strut. This video highlights the placement of an extended spreader graft made with fresh frozen allograft. Afterward, a columellar strut is placed and secured into place with intercrural mattress sutures. The spreader grafts help straighten the dorsal aesthetic lines and the columellar strut strengthens the weak medial crura.] For each particular graft, the rectangular block of fresh frozen costal cartilage is soaked in normal saline to thaw the cartilage and minimize warping. After thawing is complete, the cartilage block is symmetrically carved using a no. 10 blade. Each graft is shaped accordingly depending on its use. Grafts are secured to the underlying tissue or to each other with 4-0 polydioxanone suture.

The operation reports of each rhinoplasty and any associated complications such as infection, resorption, and warping were recorded. Standardized photographs were performed for each patient during all preoperative and postoperative visits. Resorption is defined as a visible deformity seen at the site of graft placement at follow-up visits. Warping is defined as noticeable deviation at the site of graft placement at follow-up visits.

To assess the aesthetic outcomes of the procedure, an objective evaluation of aesthetic results was performed by four blinded plastic surgeons. These surgeons reviewed preoperative and postoperative photographs of the patients in the study cohort. The outcomes were assessed using the Independent Rhinoplasty Outcome Score (Table 2). The following components are assessed: symmetry, dorsal height, dorsal length, dorsal width, tip projection, tip rotation, tip width, and overall result.

**RESULTS**

The average follow-up period was 3.35 months (range, 1 to 18 months) for patients who underwent revision rhinoplasty with fresh

**Table 2. Independent Rhinoplasty Outcome Score\***

Symmetry
Dorsal length
Dorsal width
Dorsal height
Tip width
Tip projection
Alar width
Alar shape
Overall result

\*Each factor is scored from 1 to 4, with 1 = no improvement, 2 = moderate outcome, 3 = good outcome, and 4 = excellent outcome.

**Table 3. Types of Grafts Used**

Type of Graft	No. (%)
Dorsal augmentation	15 (30)
Alar contour	44 (88)
Dorsal spreader	8 (16)
Columellar strut	14 (28)
Infratip	8 (16)
Septal extension	3 (6)

frozen nonirradiated cartilage allograft. The mean patient age was 40 years (range, 21 to 70 years). The average number of prior rhinoplasties was 2.62. The average operative time was 159 minutes (range, 70 to 370 minutes). Types of grafts used are summarized in Table 3.

There was only one complication in this cohort, which was infection [one of 50 patients (2 percent)]. This complication was treated with minimal débridement and a short course of antibiotic therapy. There were no cases of warping or resorption in this cohort. Results for evaluation of the aesthetic outcomes by blinded surgeons is summarized in Table 4. The average score for each component of the Independent Rhinoplasty Outcome Score was greater than 3 (good outcome).

**DISCUSSION**

Autologous cartilage is the predominant donor cartilage graft used in revision rhinoplasty.<sup>14</sup> The cartilages are generally harvested from the ear when the requirements are low, but in most cases, costal cartilage is harvested. There are studies touting the use of costal cartilage in revision rhinoplasty<sup>15</sup> and further reports that describe suturing and carving techniques to minimize warping.<sup>16-18</sup> Despite these advantages, costal cartilage is associated with postoperative pain and prolonged operating times. One of the risks with costal cartilage harvest is inadvertent opening of the pleural cavity (0.1 to 2.1 percent), which may result in pneumothorax.<sup>19</sup> In contrast

**Table 4. Average Score and Range for Each Component of the Independent Rhinoplasty Outcome Score**

Component	Average	Range
Symmetry	3.13	2.25-4
Dorsal length	3.105	1.75-4
Dorsal width	3.065	2-4
Dorsal height	3.115	2-4
Tip width	3.165	1.75-4
Tip projection	3.255	1.75-4
Alar width	3.23	2.25-4
Alar shape	3.19	1.5-4
Overall shape	3.22	2.5-4

to traumatic pneumothorax, the visceral pleura is usually spared, eliminating the need for a formal tube thoracostomy. Closing the rent with the anesthesiologist giving positive-pressure ventilation usually suffices. Pain caused by cartilage harvest may limit chest expansion, resulting in postoperative atelectasis and the need for prolonged narcotic pain control.<sup>20</sup> Many patients may not feel comfortable having a scar associated with costal cartilage harvest,<sup>21</sup> because the majority of surgeons do not use a limited incision technique.<sup>22</sup>

Harvested costal cartilage needs to be shaped appropriately, but it is at risk for warping. Central core of the ribs and ribs with a larger cross-sectional area tend to warp less.<sup>16</sup> Despite careful carving techniques and oppositional suturing, the cartilage can still warp. In older patients, the cartilage can be very stiff and not suitable for certain types of rhinoplasty grafts (i.e., tip grafts). In contrast, in some patients, the costal cartilage can be very pliable and soft, which means it is at greater risk for warping and not meant to be used in areas needing stiffer, structural grafts (i.e., dorsal onlay grafts).

Warner et al. published the results of their National Interdisciplinary Rhinoplasty Survey and found that 32 percent of surgeons performed fewer than 10 rhinoplasties per year, and another 32 percent performed between 11 and 20 rhinoplasty cases per year.<sup>23</sup> With many surgeons not performing the procedure frequently, harvesting costal cartilage can require more intraoperative time, adding to the overall cost of the procedure. This cost can outweigh the cost of purchasing fresh frozen nonirradiated allograft.

Irradiated cartilages were introduced and used in revision rhinoplasty because they are not associated with donor-site morbidity or increased operative times. Cartilage allografts were sterilized and the antigenicity was reduced by irradiating the cartilages. Wee et al. compared the outcomes of autologous grafts and irradiated grafts and found that resorption was significantly higher among the irradiated grafts (30 percent) compared with the autologous grafts (3 percent).<sup>24</sup> They further compared the histology of both types of grafts and found that irradiated cartilages show a decrease in chondrocyte viability and collagen fiber content. The process of irradiation adversely affects the viability of the graft. This finding was supported by another study by Welling et al. where they noted a 75 percent resorption rate, resulting in poor satisfaction levels in many patients.<sup>25</sup> However, there are reports in the literature where irradiated cartilage is shown to have comparable complication

**Table 5. Comparison of Autografts, Irradiated Allografts, and Fresh Frozen Nonirradiated Allografts for Use in Revision Rhinoplasty**

Complication	Autologous (%) <sup>*</sup>	Irradiated (%) <sup>*</sup>	Fresh Frozen (%)
Warping	13	10	0
Infection	6	10	2
Resorption	3	30	0
Pneumothorax	2	N/A	N/A
Donor-site pain	0	N/A	N/A
Total no. of complications	27	45	2

N/A, not applicable.

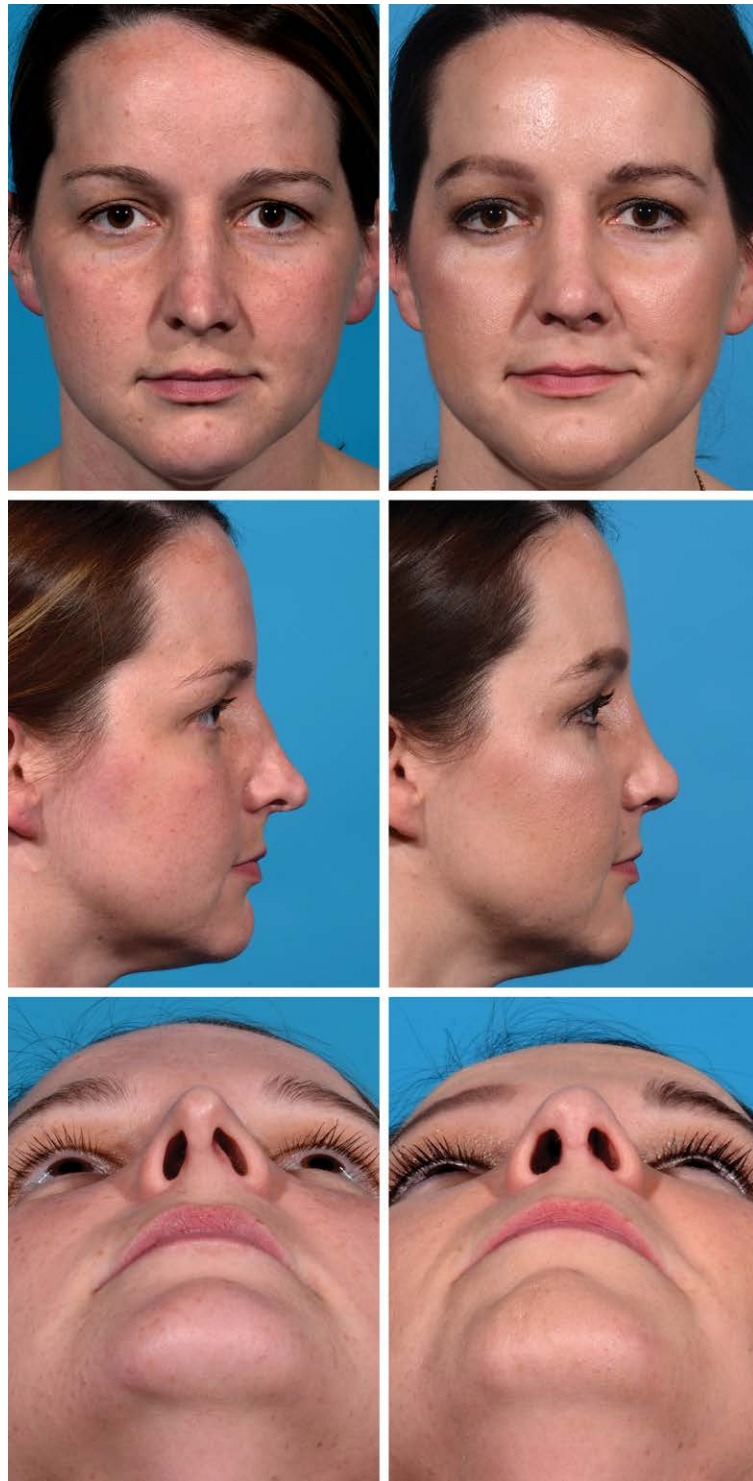<sup>\*</sup>Wee JH, Park MH, Oh S, Jin HR. Complications associated with autologous rib cartilage use in rhinoplasty: A meta-analysis. *JAMA Facial Plast Surg*. 2015;17:49–55.

rates with autologous grafts.<sup>11</sup> Over time, though, the use of irradiated cartilage has fallen out of favor in revision rhinoplasty because of the generally higher rates of resorption and infection.<sup>26</sup>

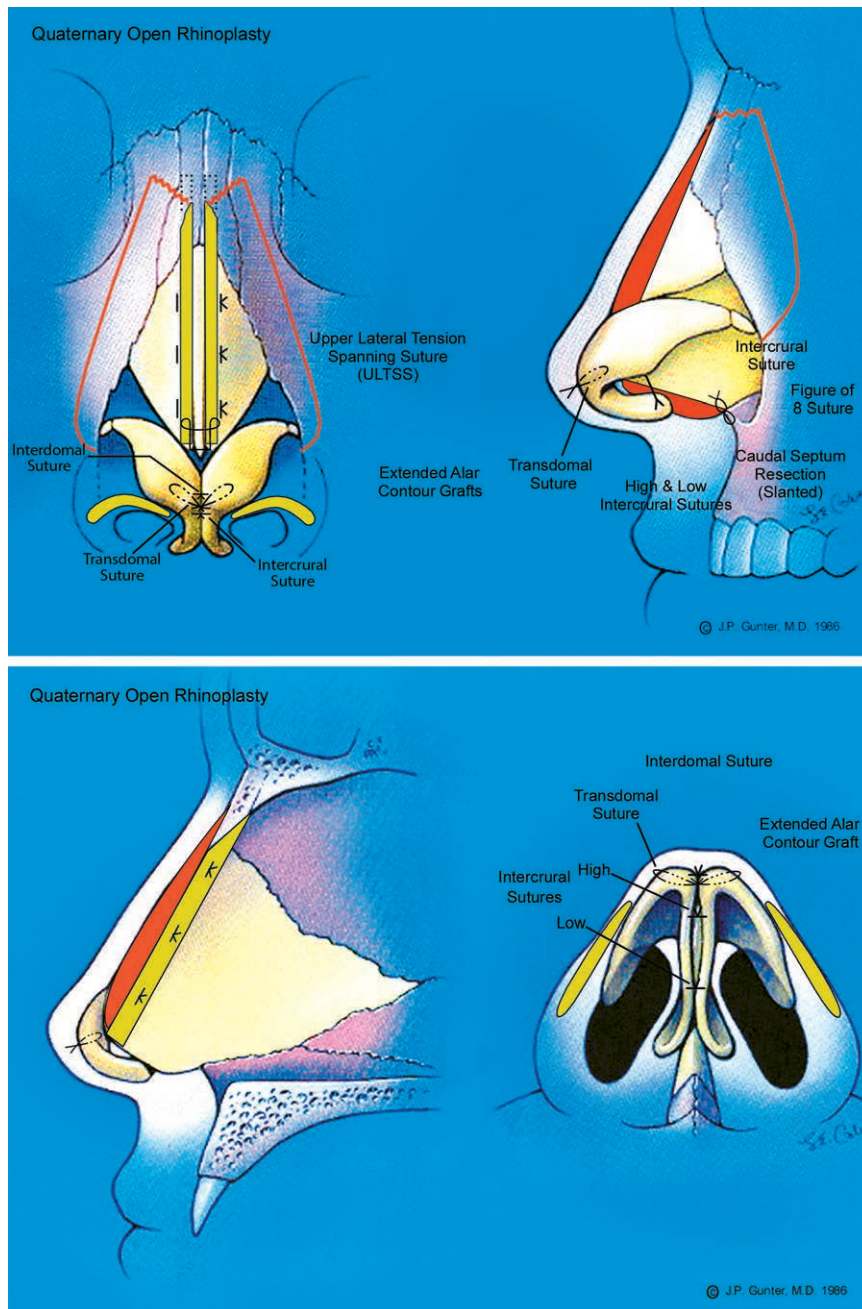
We analyzed preliminary outcomes of the use of fresh frozen allograft to fashion various types of grafts in revision rhinoplasty. Our early results showed a very low complication rate with the use of these allografts (Table 5). Our results showed that these allografts were primarily used for dorsal only grafts, tip grafts, spreader grafts, and alar contour grafts. Based on objective assessments of the postoperative photographs, the average ratings for each component of the Independent Rhinoplasty Outcome Score was greater than 3 (good outcome). In terms of overall outcome ratings, the majority of patients were rated to have a good or excellent outcome. We also believe that we witnessed a lower complication rate because these grafts were not irradiated. Once harvested, they are treated with an antibiotic solution and surrounding soft tissues are débrided. The graft is minimally altered and its viability is maintained by storing at subzero temperatures.<sup>27</sup> Two representative cases of patients undergoing revision rhinoplasty with fresh frozen cartilage allograft are shown (Figs. 1 and 2 for the first case and Figs. 3 and 4 for the second case.)

The use of fresh frozen rib cartilage allograft appears to have the benefits of irradiated cartilage without the downsides based on our early results. The processing of the grafts sterilizes them and appears not to affect the viability because there is no irradiation. We did not witness any cases of resorption in our cohort. To elucidate why, further studies would need to be performed analyzing the histology of the grafts and assessing the patients over a longer period. In our experience, we found that allografts with a more yellowish hue are thicker and stiffer. These grafts are most





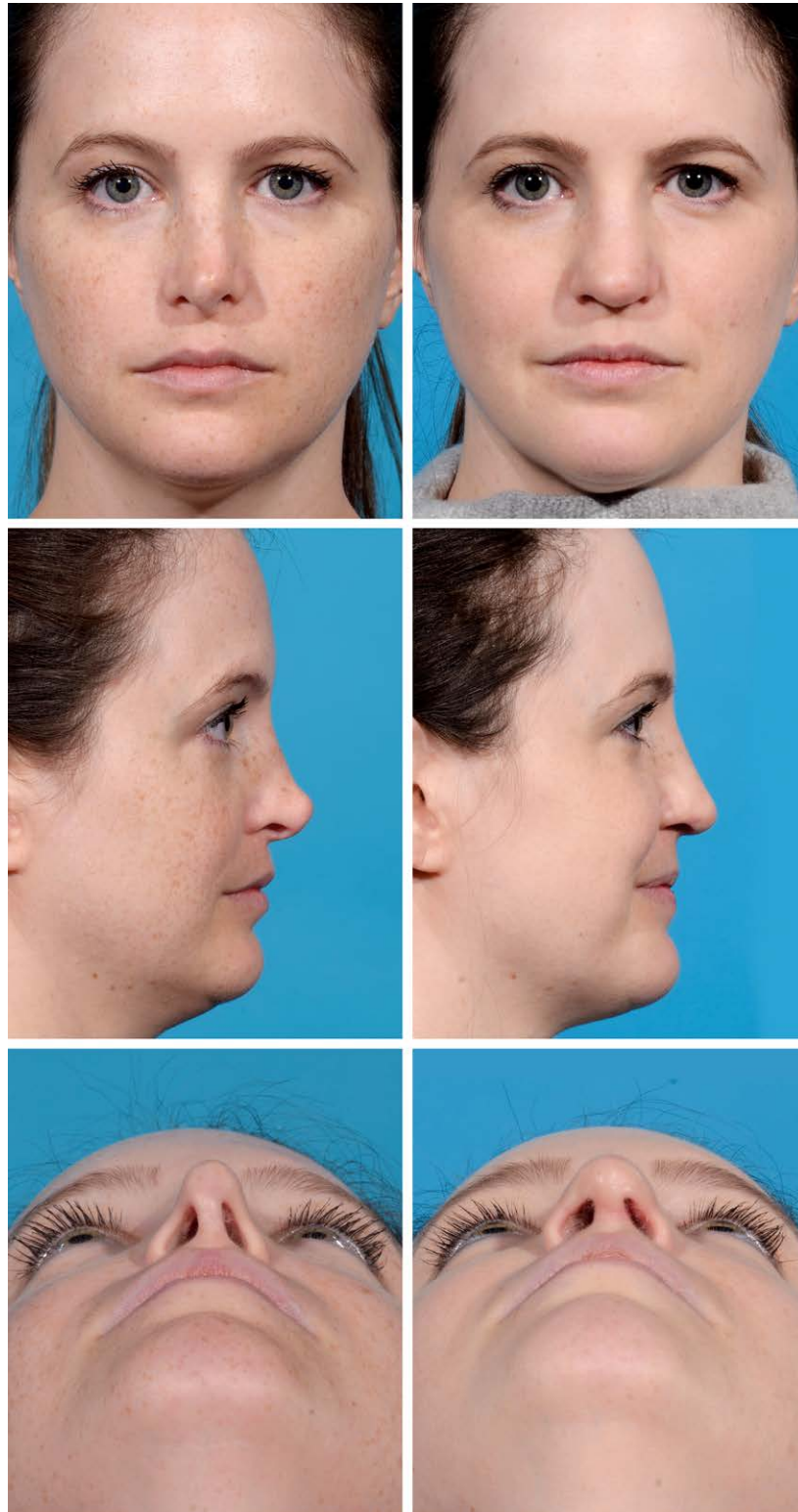**Fig. 1.** A 32-year-old patient who desired revision rhinoplasty to address functional and aesthetic deformities of her nose. She presented with nasal asymmetry, inverted-V deformity, and an oversculpted appearance of her tip. She underwent open, tertiary rhinoplasty using fresh frozen graft because there was inadequate septal cartilage. Her postoperative result (13 months postoperatively) shows improved symmetry and straightening of her nose. She reported improved breathing. She had appropriate tip projection with a slight supratip break.



**Fig. 2.** The 32-year-old patient featured in Figure 1 underwent open quaternary rhinoplasty through a transcolumellar approach. Component dorsal reduction was performed with bilateral percutaneous osteotomies and dorsal spreader grafts using fresh frozen allograft to balance the dorsal aesthetic lines and restore the midvault. The tip was refined using transdomal, intercrural, and interdomal sutures. Extended alar contour grafts were placed to support the external nasal valve.

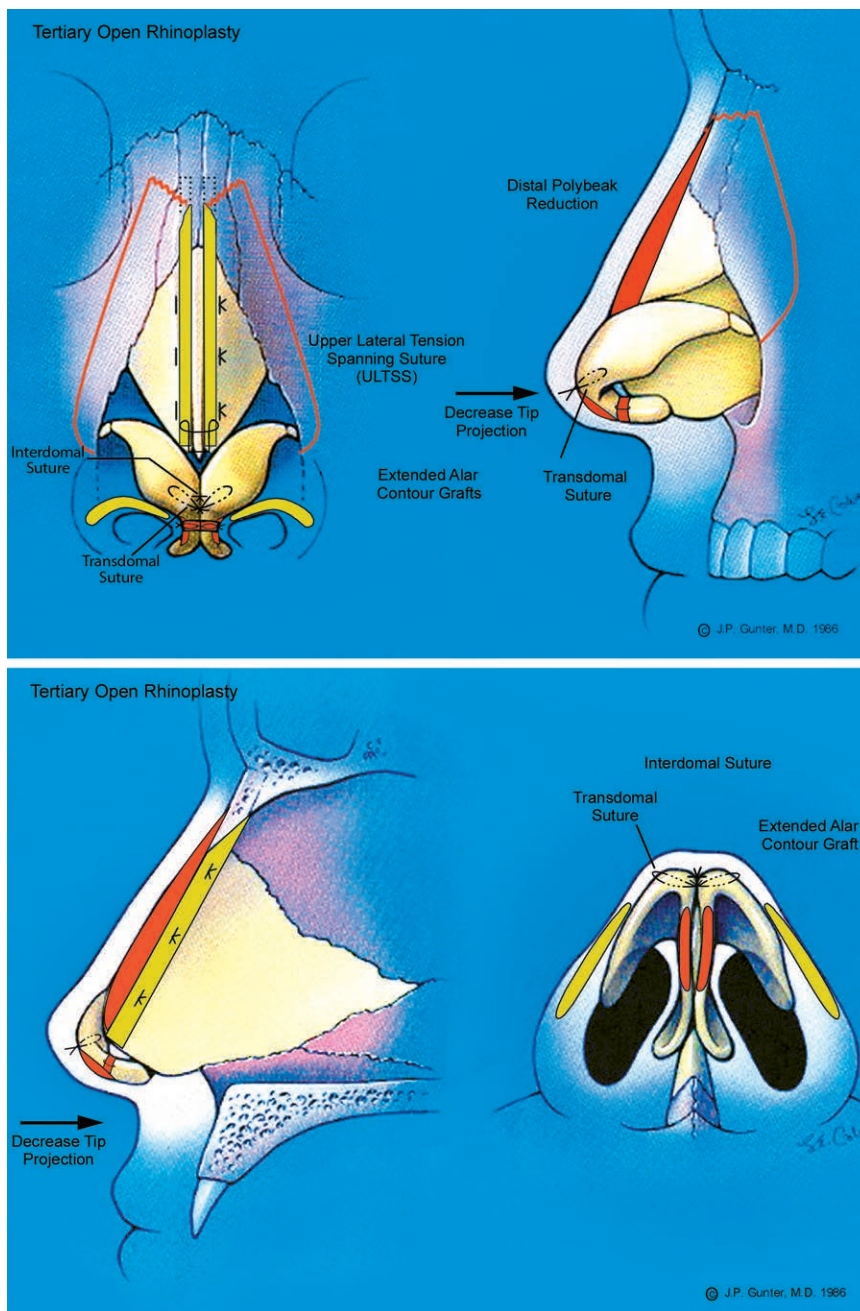
suiting for situations that require more support in the nose. In contrast, allografts that were pale or had a whitish hue are thinner and more pliable and are more likely to warp. These allografts are much better suited for areas of the nose requiring softer grafts that provide contour. One particular piece of allograft can either provide more

support or better contour but cannot do both, because it depends on the pliability and thickness of the allograft material. [See Video 5 (online), which shows a description of grafts. Fresh frozen allografts are derived from cadavers of different ages. The cartilages from younger specimens are lighter in color and more pliable. They are at



**Fig. 3.** A 33-year-old patient who desired revision rhinoplasty to address functional and aesthetic deformities of her nose. She presented with nasal asymmetry, alar notching, and an overrotated tip. She underwent open, tertiary rhinoplasty using fresh frozen graft because there was inadequate septal cartilage. Her postoperative result (16 months postoperatively) shows improved symmetry and straightening of her nose. Her tip has better projection and rotation.





**Fig. 4.** The 33-year-old patient featured in Figure 3 underwent open tertiary rhinoplasty through a transcolumellar approach. Distal pollybeak reduction was performed by removing 2 mm of distal septal scar. Bilateral percutaneous osteotomies and dorsal spreader grafts using fresh frozen allograft were placed to refine the dorsal aesthetic lines and breathing difficulty. The tip was refined using transdomal and interdomal sutures. Medial crural transection and overlap was performed to decrease tip projection. Extended alar contour grafts were placed to support the external nasal valve.

greater risk for warping and are primarily used for tip grafts and alar contour grafts because they are less visible. The darker, more stiffer grafts are from older specimens and are better suited for dorsal augmentation and septal extension grafts. **See Figure, Supplemental Digital Content 1**, which shows

that the top fresh frozen nonirradiated allograft is white in appearance and is from a younger donor source. These grafts tend to be softer and more pliable but are at greater risk for warping. They are best suited for tip or alar contour grafts. The middle graft is darker and stiffer relative to the above



graft. The bottom graft is much darker and stiffer than the other grafts shown and is meant for structural grafts intended to provide support (i.e., dorsal onlay grafts and dorsal spreader grafts), <http://links.lww.com/PRS/D643>.]

A major difficulty of this fresh frozen nonirradiated cartilage graft is that it should be stored and transported at temperatures between  $-40^{\circ}$  and  $-80^{\circ}\text{C}$ . The cartilage is shipped in a special container on dry ice to maintain this temperature, which increases the cost of transport of the material. The cost of storage is also higher because a noncommercial freezer is required to maintain this temperature.

The limitations of the study are the sample size and short follow-up period in our cohort. A study comparing the clinical outcomes and histology of fresh frozen nonirradiated cartilage grafts, irradiated grafts, and autografts would further advance our understanding of how these cartilage grafts behave. In addition, a study examining different types of colored allografts and their properties would help surgeons determine which pieces are best suited for their cases. We believe that fresh frozen cartilage allograft is an evolving source of cartilage in revision rhinoplasty because there is an abundance of grafting material and the complication rate and operative time appears to be relatively lower compared with other cartilage sources.

**Rod J. Rohrich, M.D.**

Dallas Plastic Surgery Institute  
9101 North Central Expressway, Suite 600  
Dallas, Texas 75231  
Rod.rohrich@dpsi.org  
Twitter: @DrRodRohrich  
Instagram: @Rod.Rohrich

## PATIENT CONSENT

*Patients provided written consent for the use of their images.*

## REFERENCES

1. Rees TD, Krupp S, Wood-Smith D. Secondary rhinoplasty. *Plast Reconstr Surg*. 1970;46:332–340.
2. Neaman KC, Boettcher AK, Do VH, et al. Cosmetic rhinoplasty: Revision rates revisited. *Aesthet Surg J*. 2013;33:31–37.
3. Spataro E, Piccirillo JF, Kallogerji D, Branham GH, Desai SC. Revision rates and risk factors of 175,842 patients undergoing septorhinoplasty. *JAMA Facial Plast Surg*. 2016;18:212–219.
4. Goudakos JK, Daskalakis D, Patel K. Revision rhinoplasty: Retrospective chart review analysis of deformities and surgical maneuvers in patients with nasal airway obstruction: Five years of experience. *Facial Plast Surg*. 2017;33:334–338.
5. Thomson C, Mendelsohn M. Reducing the incidence of revision rhinoplasty. *J Otolaryngol*. 2007;36:130–134.
6. Gunter JP, Rohrich RJ. Augmentation rhinoplasty: Dorsal onlay grafting using shaped autogenous septal cartilage. *Plast Reconstr Surg*. 1990;86:39–45.
7. Wee JH, Park MH, Oh S, Jin HR. Complications associated with autologous rib cartilage use in rhinoplasty: A meta-analysis. *JAMA Facial Plast Surg*. 2015;17:49–55.
8. Cakmak O, Ergin T. The versatile autogenous costal cartilage graft in septorhinoplasty. *Arch Facial Plast Surg*. 2002;4:172–176.
9. Moretti A, Sciuto S. Rib grafts in septorhinoplasty. *Acta Otorhinolaryngol Ital*. 2013;33:190–195.
10. Menger DJ, Nolst Trenité GJ. Irradiated homologous rib grafts in nasal reconstruction. *Arch Facial Plast Surg*. 2010;12:114–118.
11. Kridel RW, Ashoori F, Liu ES, Hart CG. Long-term use and follow-up of irradiated homologous costal cartilage grafts in the nose. *Arch Facial Plast Surg*. 2009;11:378–394.
12. Kichura ALP, Chen AC, Wong MMT, Bugbee WD, Sah RL. In vivo efficacy of fresh vs. frozen osteochondral allografts in the goat at 6 months is associated with PRG4 secretion. *J Orthop Res*. 2013;31:880–886.
13. Overby C. Surgical consultant, Musculoskeletal Transplant Foundation, (Edison, N.J.). Personal communication with Raja Shanmugha Krishnan (Ganga Hospital, Coimbatore, India), April 5, 2018.
14. Moon BJ, Lee HJ, Jang YJ. Outcomes following rhinoplasty using autologous costal cartilage. *Arch Facial Plast Surg*. 2012;14:175–180.
15. Toriumi DM. Discussion: Use of autologous costal cartilage in Asian rhinoplasty. *Plast Reconstr Surg*. 2012;130:1349–1350.
16. Kim DW, Shah AR, Toriumi DM. Concentric and eccentric carved costal cartilage: A comparison of warping. *Arch Facial Plast Surg*. 2006;8:42–46.
17. Farkas JP, Lee MR, Rohrich RJ. Technical maneuvers to decrease warping of peripheral costal cartilage grafts. *Plast Reconstr Surg*. 2016;138:228e–232e.
18. Farkas JP, Lee MR, Laktionhi C, Rohrich RJ. Effects of carving plane, level of harvest, and oppositional suturing techniques on costal cartilage warping. *Plast Reconstr Surg*. 2013;132:319–325.
19. Marin VP, Landecker A, Gunter JP. Harvesting rib cartilage grafts for secondary rhinoplasty. *Plast Reconstr Surg*. 2008;121:1442–1448.
20. Kwok MM. Post-rib harvesting pain should be considered as a potential significant morbidity in reconstructive rhinoplasty. *JAMA Facial Plast Surg*. 2015;17:226.
21. Lee MJ, Song HM. Asian rhinoplasty with rib cartilage. *Semin Plast Surg*. 2015;29:262–268.
22. Adamson PA, Warner J, Becker D, Romo TJ III, Toriumi DM. Revision rhinoplasty: Panel discussion, controversies, and techniques. *Facial Plast Surg Clin North Am*. 2014;22:57–96.
23. Warner J, Gutowski K, Shama L, Marcus B. National interdisciplinary rhinoplasty. *Aesthet Surg J*. 2009;29:295–301.
24. Wee JH, Mun SJ, Na WS, et al. Autologous vs irradiated homologous costal cartilage as graft material in rhinoplasty. *JAMA Facial Plast Surg*. 2017;19:183–188.
25. Welling DB, Maves MD, Schuller DE, Bardach J. Irradiated homologous cartilage grafts: Long-term results. *Arch Otolaryngol Head Neck Surg*. 1988;114:291–295.
26. Toriumi DM. Choosing autologous vs irradiated homograft rib costal cartilage for grafting in rhinoplasty. *JAMA Facial Plast Surg*. 2017;19:188–189.
27. Tomford WW, Fredericks GR, Mankin HJ. Studies on cryopreservation of articular cartilage chondrocytes. *J Bone Joint Surg Am*. 1984;66:253–259.