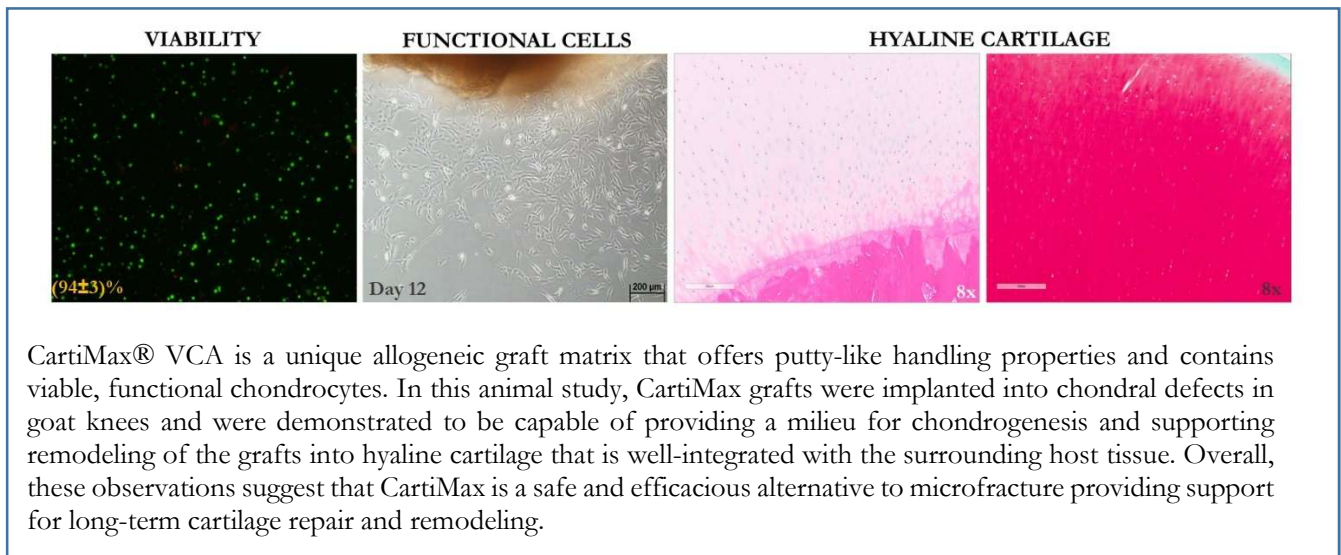


# Long-term Follow-Up of Focal Cartilage Defects Repair with CartiMax<sup>®</sup> Viable Cartilage Allograft in a Goat Model

MTF Biologics, Research and Development Department  
125 May Street, Edison, NJ 08837



## INTRODUCTION & BACKGROUND

CartiMax® Viable Cartilage Allograft (VCA) is a cryopreserved allogeneic tissue graft that combines the benefits of viable chondrocytes with putty-like handling characteristics which allows the surgeon to easily fill cartilaginous defects of various shapes and sizes. This advanced cartilage treatment solution provides the foundation of matrix proteins, growth factors and adherent viable cells to facilitate articular cartilage repair of chondral defects. CartiMax has two components: viable cartilage fibers and cartilage allograft matrix (CAM). Viable cartilage fibers are processed and cryopreserved to achieve optimal viability. CAM is lyophilized cartilage extracellular matrix (ECM) that contains key endogenous growth factors and proteins. In this study, CartiMax VCA was evaluated for safety and efficacy when implanted in goat knees in comparison with microfracture for the treatment of critical-sized, focal cartilage defects, up to 1 year.

## METHODOLOGY

### Characterization of CartiMax Grafts Prior to Implantation:

The cryopreserved cartilage fiber component of CartiMax VCA was characterized for cell viability and cell functionality. Samples from the same donor that were implanted in this animal study were used for these *in vitro* studies. The CAM component has been previously characterized<sup>1</sup>. To determine cell viability, the cryopreserved cartilage fiber component was thawed as per the package insert, enzymatically digested with collagenase II to remove the cartilage ECM and isolate the chondrocytes. The chondrocytes were then stained using the Live/Dead Viability Toxicity Kit (Molecular Probes, Invitrogen) to visualize viable and dead cells. Stained sections were imaged (n=15) under 10x magnification using a fluorescent microscope (Leica Microsystems). Viable (green stained) and dead (red stained) cells were enumerated in each field to establish the percentage of viable cells. Furthermore, to verify that the viable cells are functional (have the ability to migrate and proliferate), cartilage fibers were placed onto tissue culture-treated plates with basal culture medium. Cartilage fibers were monitored to visualize cells that had migrated out of the tissue and onto the surface of the culture plates, and allowed to proliferate to confluency.

### Animal Study Design/Surgical Implantation:

The goat model is frequently used as a large animal model (given the cartilage thickness and relative large joint size of the knee) for the investigation of cartilage repair (FDA Committee Meeting #38, March 2005) and was the choice for this study. Using this model, microfracture has been previously reported to yield better results in the lateral patellar sulcus compared to the medial femoral condyle (MFC)<sup>2</sup>. Therefore, in this study, microfracture was performed in the trochlea sulcus to represent a clinically-similar and challenging control group while CartiMax VCA was implanted in an MFC focal defect in the same goat in order to conserve animals. Critical-sized defects (6mm diameter)<sup>3, 4</sup> were surgically created in the trochlear sulcus and MFC in non-pregnant female Spanish goats (IBEX Preclinical Research, Inc., Logan, UT). The animals were housed at IBEX Preclinical Research for the duration of the study. The goats were maintained in large indoor pens, splinted for 6 weeks and monitored daily for general health concerns throughout the course of the study. The study time-points were 12, 24 and 52 weeks post-implantation. Animals were humanely euthanized according to the AVMA Panel on Euthanasia guidelines<sup>5</sup>. CartiMax VCA was aseptically processed and cryopreserved without terminal sterilization at MTF Biologics (Edison, NJ). CartiMax units were thawed and prepared for implantation at the site according to the package insert. All implants were from a same donor of CartiMax VCA, which was the same lot as the one utilized in the *in vitro* characterization studies.

### Histological Assessment from Goat Study:

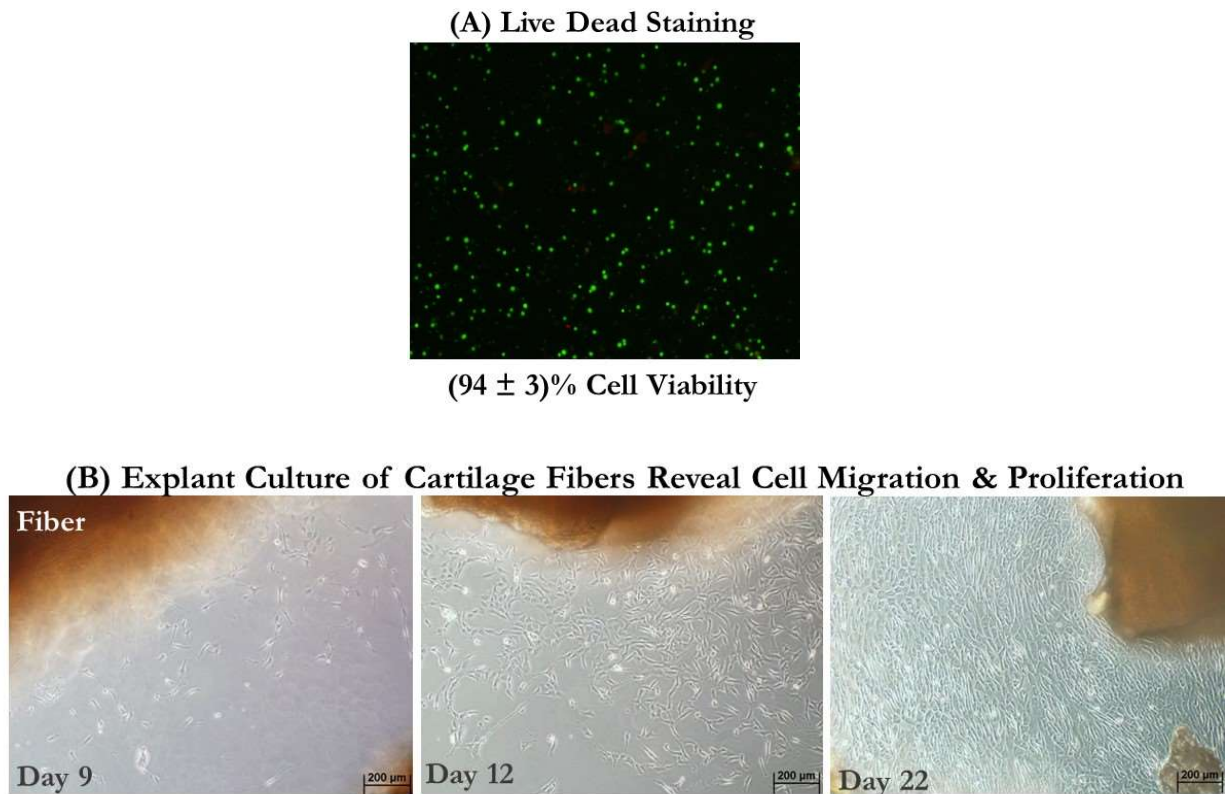
Following animal sacrifices, osteochondral biopsies were harvested and fixed in 10% neutral buffered formalin. The right and left popliteal lymph nodes were also harvested and fixed to examine any histological changes over time. All biopsies were decalcified, trimmed in half through the center, embedded and processed using

standard histological techniques (Premier Laboratories, LLC, Boulder, CO). Histologic sections were stained for safranin-O (proteoglycans), collagen type II, collagen type I and H&E.

## RESULTS

### **CartiMax VCA contains viable and functional cells:**

Cell viability of the cartilage fiber component of CartiMax VCA was measured at  $94 \pm 3\%$  from the Live/Dead analysis post-thaw. Explanted tissue cultures confirmed that viable cells migrated from the cartilage fibers onto the tissue culture plate surface as early as day 9. These cells subsequently proliferated as shown by day 12 demonstrating that the cells were functional and ultimately became confluent (expanded cells covered the entire plate) by day 22 (Figure 1).



**Figure 1:** Pre-implantation characterization of cryopreserved cartilage fibers found in CartiMax VCA. (A) Representative live/dead staining of viable chondrocytes. (B) Viable chondrocytes in the cartilage fibers are functional as they migrated out from the cartilage fiber by day 9 and proliferated to confluency by day 22.

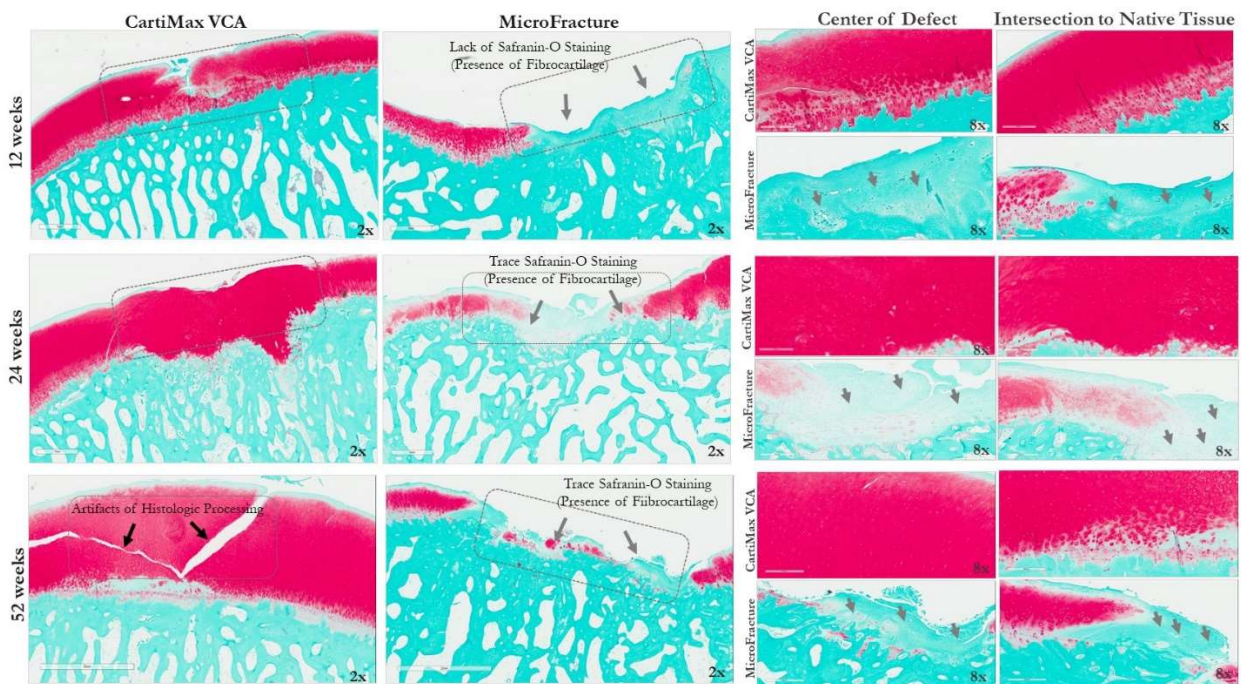
### **CartiMax VCA safely supported cartilage repair in a long-term follow-up goat focal chondral defect animal model:**

No adverse effects were noted over the duration of the animal study. In addition, the popliteal lymph nodes (left/right) were biopsied and stained, revealing no changes in the nodes. These observations indicated a positive safety profile for CartiMax VCA when implanted in the goats for the duration of this study.

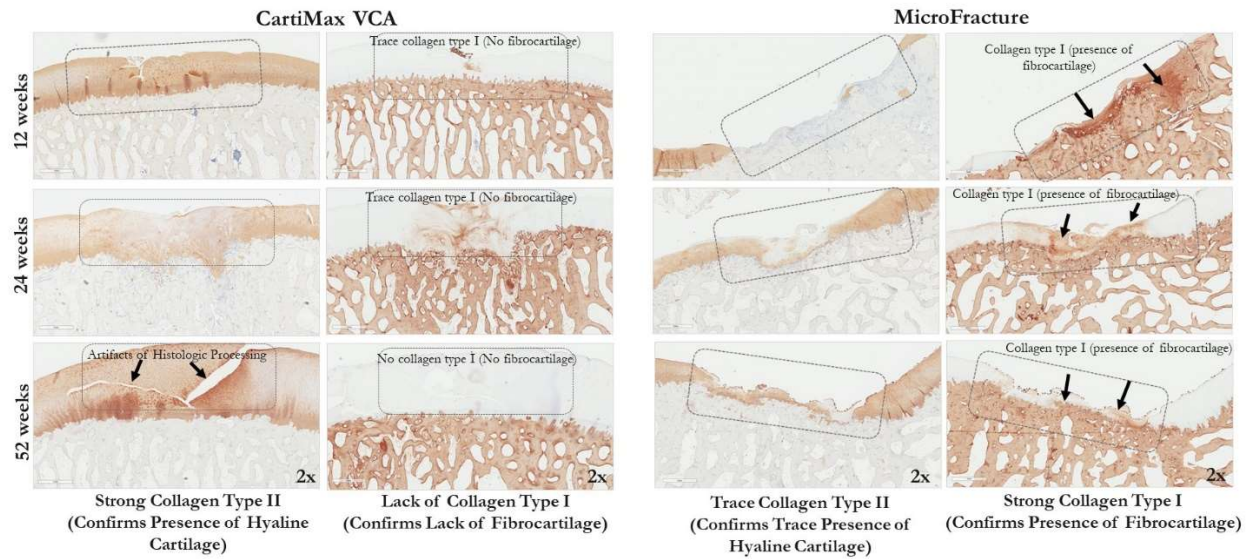
Histological staining of the treated goat chondral defects confirmed that CartiMax VCA can support functional chondrogenic activity leading to significant graft remodeling and cartilage repair over time. Prominent safranin-O (evidence of proteoglycans) and collagen type II staining, which are critical components of hyaline cartilage,

were observed by 12 weeks and were sustained over time at 24 and 52 weeks (Figures 2 and 3). In contrast, with the microfracture treatment, only trace levels of safranin-O and collagen II were detected, indicating a lack of hyaline cartilage formation. Instead, incomplete fill of the defect sites and the presence of fibrous tissue (fibrocartilage) was observed (Figure 3 and 4).

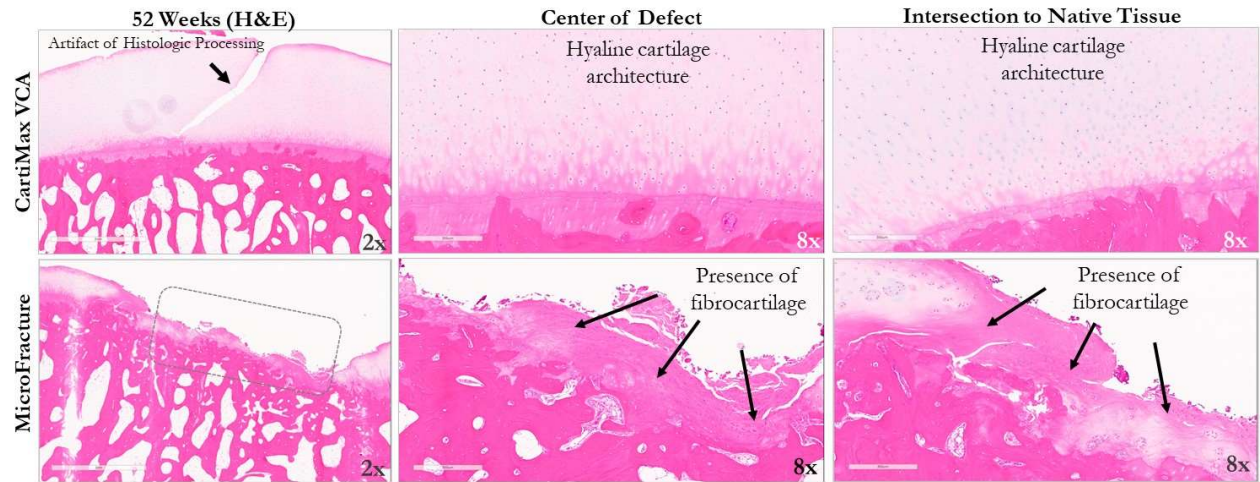
A closer examination of safranin-O staining at the defect site reveals stronger, denser proteoglycan deposition with the CartiMax VCA treatment over time (Figure 2). The defect area is well integrated both laterally (to the cartilage edges) and vertically (to the subchondral bone) with the native tissue and consistent across the entire area. However, with the microfracture treatment, the safranin-O staining is diffuse and punctate across the defect area over time, and the cartilage morphology appears to be consistent with fibrocartilage. This is further confirmed with trace collagen type II staining within the defect in the microfracture treatment (Figure 3) along with a lack of edge integration and positive collagen type I staining, which is indicative of fibrocartilage. With CartiMax VCA, there is strong collagen type II staining and lack of collagen type I, along with cell morphology structure that is consistent with articular hyaline cartilage.



**Figure 2:** Comparison of safranin-O staining (evidence of proteoglycans) in CartiMax VCA versus microfracture treatment in focal goat knee defects (as shown by the dotted boxes) over time (2x magnification) – representative (nominal) samples/pictures. Prominent safranin-O staining is observed in the CartiMax VCA treatment confirming extensive chondrogenic function by 12 weeks, and this was sustained over time at 24 and 52 weeks. Safranin-O is a characteristic component of hyaline articular cartilage. This robust staining was observed throughout the cartilage surface in the CartiMax VCA group, with lateral and vertical integration of the graft to the adjacent native goat cartilage and subchondral bone (center and edge intersection images at 8x magnification). The gap in the cartilage region in the 52 week image for the CartiMax VCA group is an artifact of histologic processing. In contrast, there was trace levels of safranin-O staining in the microfracture treatment, with the presence of more fibrous tissue (grey arrows) across the cartilage surface and native tissue intersection/edge.



**Figure 3:** Collagen type II (evidence of hyaline cartilage) and collagen type I (evidence of fibrocartilage) staining in CartiMax VCA and microfracture over time (2x magnification). Distinct positive collagen type II staining (defect area outlined by the dotted box) was observed in the CartiMax VCA treatment, with the lack to trace levels of collagen type I (lack of fibrocartilage) staining (as shown in the dotted box). In contrast, in the microfracture treatment, there was more collagen type I staining (indicative of fibrocartilage) with trace levels of collagen type II staining (dotted box). Collagen type I is indicative of the presence of fibrocartilage, and is not present in hyaline cartilage. The gap in the cartilage region in the 52 week image for the CartiMax VCA group is an artifact of histologic processing.



**Figure 4:** H&E staining at 52 weeks, further confirms hyaline architecture in the CartiMax VCA group compared to fibrocartilage morphology (black arrows) found in the microfracture treatment (center and edge intersection images at 8x magnification). The gap in the cartilage region in the 52 week image for the CartiMax VCA group is an artifact of histologic processing.

## DISCUSSION

This animal study provides evidence that CartiMax VCA is a safe, off-the-shelf, viable tissue biologic treatment option for full thickness cartilage lesions that has the ability to support the remodeling of hyaline components including proteoglycans, and collagen type II and structure that closely resemble native articular cartilage. The remodeled tissue can completely fill the defect site and is maintained over time up to 52 weeks post-surgery. While microfracture is the current standard of care for treating focal cartilage defects<sup>6</sup>, the resulting fibrocartilaginous repair tissue is not durable to maintain positive clinical outcomes over an extended period of time<sup>7</sup>.

In order to successfully repair hyaline cartilage, it has been reported that viable, functional chondrocytes are required along with a suitable microenvironment that will provide both structural support and appropriate biochemical signals<sup>8</sup>. CartiMax VCA implants provide endogenous viable chondrocytes within a natural chondroprotective matrix of human cartilage fibers. The *in vitro* CartiMax VCA characterization results demonstrate that viable and functional chondrocytes are preserved during processing and cryopreservation. Furthermore, the CAM component has previously been shown to possess natural, endogenous growth factors (IGF-1, TGF- $\beta$ , FGF-2)<sup>1,9</sup>, which are reported to support chondrogenesis<sup>10</sup>. Once the viable cartilage fibers and CAM are combined yielding CartiMax VCA, the putty-like handling characteristics can allow the defects of various shapes and sizes in cartilage to be filled easily. In addition, the moldability of the graft may support better integration with the surrounding host tissue, reducing potential void space and contributing to a more complete fill. Taken together, the CartiMax VCA graft has the key ingredients to facilitate chondrogenic activities in the cartilage defect and may lead to long-term favorable results in a clinical setting.

From this goat study, the histological data of the CartiMax VCA-treated defects revealed chondrogenic activity with intense, positive proteoglycan and collagen type II staining (lack of collagen type I), and robust integration at the edges to the native goat tissue (both to the cartilage edges and subchondral bone). The proteoglycan and collagen type II staining was strong and sustained over time, demonstrating critical hyaline cartilage organization in the newly formed tissue. The viable, functional cells in the cartilage fibers may participate in supporting this sustained activity. From literature, the presence of proteoglycans and collagen type II network facilitates a chondrogenic environment providing elasticity and lubrication to the joint<sup>11</sup>. In contrast, at each time point, microfracture yielded incomplete fill and diffuse proteoglycan and collagen type II staining, but positive collagen type I staining over time, exhibiting the typical fibrocartilage structure<sup>12</sup>, found in both animal and human studies<sup>7</sup>. Moreover, this goat study findings are consistent with the initial, positive clinical reports of patients treated with CartiMax VCA, which have further demonstrated early improvements in both pain and function<sup>9</sup>. Longer-term assessments of these patients are in progress.

## CONCLUSION

CartiMax VCA is a unique allogeneic graft matrix that offers putty-like handling properties and contains viable, functional chondrocytes. In this animal study, once implanted into a cartilage defect, the combination of the viable chondrocytes and the natural cartilaginous matrix provide a milieu for chondrogenesis and support remodeling of the graft into hyaline cartilage that is well-integrated with the surrounding host tissue. Overall, these observations in an animal model suggest that CartiMax is a safe and efficacious alternative to microfracture that has the potential to provide support for long-term cartilage repair and remodeling.

## References

1. Repair of Chondral Thickness Defects Using Cartilage Allograft Matrix in a Goat Model. *Data on file* (2017).

2. T.H. Davisson, R.Z., S. Coyle, C. Aponte, M. Long, M. Hawkins Outcome of MicroFracture in Chondral Defects is Modulated by Anatomic Site in Goats. *Osteoarthritis and Cartilage* **16**, S48 (2008).
3. Meng, X. et al. Animal Models of Osteochondral Defect for Testing Biomaterials. *Biochem Res Int* **2020**, 9659412 (2020).
4. Jackson, D.W., Lalor, P.A., Aberman, H.M. & Simon, T.M. Spontaneous repair of full-thickness defects of articular cartilage in a goat model. A preliminary study. *J Bone Joint Surg Am* **83**, 53-64 (2001).
5. Leary, S., Underwood, W., Anthony, R., Cartner, S., Corey, D., Grandin, T., Greenacre, C, Gwaltney- & Brant, S., McCrackin, M.A., Meyer, R., Miller, D., Shearer, J., Yanong, R AVMA Guidelines for the Euthanasia of Animals. Schaumburg : American Veterinary Medical Association. (2013).
6. Fiegen, A. et al. Articular Cartilage Defects of the Glenohumeral Joint: A Systematic Review of Treatment Options and Outcomes. *Cartilage*, 1947603519870858 (2019).
7. Henderson, I., Lavigne, P., Valenzuela, H. & Oakes, B. Autologous chondrocyte implantation: superior biologic properties of hyaline cartilage repairs. *Clin Orthop Relat Res* **455**, 253-261 (2007).
8. Armiento, A.R., Stoddart, M.J., Alini, M. & Eglin, D. Biomaterials for articular cartilage tissue engineering: Learning from biology. *Acta Biomater* **65**, 1-20 (2018).
9. Biologics, M. Viability Characterization of CartiMax. (2018).
10. Fischer, J., Knoch, N., Sims, T., Rosshirt, N. & Richter, W. Time-dependent contribution of BMP, FGF, IGF, and HH signaling to the proliferation of mesenchymal stroma cells during chondrogenesis. *J Cell Physiol* **233**, 8962-8970 (2018).
11. Jerosch, J. Effects of Glucosamine and Chondroitin Sulfate on Cartilage Metabolism in OA: Outlook on Other Nutrient Partners Especially Omega-3 Fatty Acids. *Int J Rheumatol* **2011**, 969012 (2011).
12. Knutsen, G. et al. Autologous chondrocyte implantation compared with microfracture in the knee. A randomized trial. *J Bone Joint Surg Am* **86**, 455-464 (2004).