

# The Utilization of Fresh Frozen Cartilage in Asian Rhinoplasty: A New Approach

Rou Wan, MD\*

Joshua P. Weissman, BA†

Peter J. Ullrich, BS†

Chitang Joshi, MD†

Tokoya Williams, MD†

Robert D. Galiano, MD, FACS†.

**Summary:** Asian rhinoplasty generally requires augmentation procedures rather than reduction. Alloplastic grafts are fraught with higher complication rates. Autologous cartilage grafts are safer. However, Asian patients typically do not have adequate septal cartilages, and other autologous cartilage grafts may cause surgical site morbidities, prolonged surgical time, and complications, including warping and infection. Asian rhinoplasties were performed using fresh frozen cartilage by the senior author. Patients' demographics and medical histories were recorded. Anthropometric measurements (nasofrontal angle, nasofacial angle, nasolabial angle, and Goode ratio) were taken on two-dimensional photographs. FACE-Q scales were used to assess patient-reported outcomes. Five Asian patients underwent rhinoplasty using the fresh frozen cartilage and were followed up for an average period of  $14.2 \pm 3.35$  months. There was no resorption, warping, or infection. Anthropometric measurements showed no significant changes 2–4 months or 8–20 months after surgery. At the time of the 1-year follow-up, mean FACE-Q Satisfaction with Nose, and Satisfaction with Nostrils scores improved from  $35.2 \pm 10.06$  to  $60 \pm 15.48$  ( $P = 0.0002$ ), and  $42.6 \pm 20.31$  to  $59.8 \pm 38.21$  ( $P = 0.12$ ), respectively. Fresh frozen cadaveric cartilage is a novel option for Asian rhinoplasty. Our study demonstrated its safety and satisfying surgical outcomes. (*Plast Reconstr Surg Glob Open* 2023; 11:e4903; doi: 10.1097/GOX.0000000000004903; Published online 26 April 2023.)

## INTRODUCTION

Rhinoplasty is one of the most popular plastic surgery procedures in the United States and worldwide.<sup>1</sup> However, given the individual and ethnic variation in nasal anatomy and nasal beauty standards, rhinoplasty remains a challenge, particularly among the Asian population.<sup>2</sup> Typically, Asian patients desire augmentation rather than reductive procedures.<sup>3</sup> Many surgeons turn to alloplastic implants for augmentation rhinoplasty. Patients with implants are more likely to develop complications, including extrusion, thinning of the skin, displacement, and translucency of the implant.<sup>3</sup> Autologous cartilages are widely considered an ideal material for rhinoplasty.<sup>1</sup> However, Asian patients often do not have an abundant quantity of supplemental septal cartilage.<sup>4</sup> In

White women, areas of the septal cartilage are 861 mm<sup>2</sup>, compared with 750 mm<sup>2</sup> in Asian women.<sup>2</sup> Thus, autologous rib cartilage is a better option for Asian patients who need adequate cartilage for augmentation. However, it is associated with prolonged operative time, possible pneumothorax, hypertrophic scars, pain, additional surgical expenses, and graft warping.<sup>5,6</sup>

The fresh frozen cadaveric cartilage from the Musculoskeletal Transplant Foundation (Edison, N.J.) is a novel option for Asian rhinoplasty. In this study, we report our experience of using fresh frozen cadaveric costal allografts (CCA) in five Asian patients.

## MATERIALS AND METHODS

Patients of Eastern Asian ethnicity were selected and evaluated. Institutional review board approval and patient consent were obtained.

CCAs were harvested from the donors' seventh to ninth ribs and stored in frozen conditions ( $-40^{\circ}\text{C}$  to  $-80^{\circ}\text{C}$ ).<sup>5</sup> The temperature was maintained using dry ice during

From the \*Division of Plastic and Reconstructive Surgery, Mayo Clinic Rochester, Rochester, Minn.; and †Division of Plastic and Reconstructive Surgery, Northwestern University Feinberg School of Medicine, Chicago, Ill.

Received for publication July 26, 2022; accepted February 2, 2023.

Copyright © 2023 The Authors. Published by Wolters Kluwer Health, Inc. on behalf of The American Society of Plastic Surgeons. This is an open-access article distributed under the terms of the [Creative Commons Attribution-Non Commercial-No Derivatives License 4.0 \(CCBY-NC-ND\)](https://creativecommons.org/licenses/by-nc-nd/4.0/), where it is permissible to download and share the work provided it is properly cited. The work cannot be changed in any way or used commercially without permission from the journal.

DOI: 10.1097/GOX.0000000000004903

Disclosure statements are at the end of this article, following the correspondence information.

Related Digital Media are available in the full-text version of the article on [www.PRSGlobalOpen.com](http://www.PRSGlobalOpen.com).

shipment.<sup>5</sup> Before use for the implantation, cartilage tissue was thawed in normal saline.

Before and after photographs were taken in a standard photograph room. Anthropometric measurements on standard two-dimensional photographs were collected. Four measurements were taken, and the changes in the values between two follow-up visits were documented ( $\Delta = |\text{measurement}_{\text{visit1}} - \text{measurement}_{\text{visit2}}|$ ) to assess resorption and warping. FACE-Q scales<sup>6</sup> were used to assess patient-reported outcomes. Postoperative complications were also recorded.

### RESULTS

Five Asian rhinoplasties using CCAs were performed by the senior author (R.D.G.) between May 2018 and January 2020. Patients were followed up for an average of  $14.2 \pm 3.35$  months. Patients' demographics and medical history are displayed in Table 1.

There were no major adverse events or complications among any patients. No resorption or warping was recorded at 1-year follow-up (Fig. 1). The objective measurements are shown in Table 2;  $\Delta = |\text{measurement}_{\text{visit1}} - \text{measurement}_{\text{visit2}}|$  had a mean of 0.93 degrees, ranging from 0.01 degrees to 3.63 degrees. The FACE-Q Satisfaction with Nose and the FACE-Q Satisfaction with Nostrils include 10 and five items, respectively. A higher score indicated a higher degree of satisfaction. At the time of the 1-year follow-up, mean FACE-Q Satisfaction with Nose, and Satisfaction with Nostrils scores improved from a preoperative score of  $35.2 \pm 10.06$  to  $60 \pm 15.48$  ( $P = 0.0002$ ), and from a preoperative score of  $42.6 \pm 20.31$  to  $59.8 \pm 38.21$  ( $P = 0.12$ ), respectively.

### DISCUSSION

According to the 2019 plastic surgery report released by the American Society of Plastic Surgeons, rhinoplasty is the second most popular cosmetic surgical procedure

**Takeaways**

**Question:** Is fresh frozen cadaveric cartilage an ideal material for Asian rhinoplasty?

**Findings:** The use of fresh frozen cadaveric cartilage on Asian patients was successful. There was no infection, resorption, or warping 1 year after surgery. Allograft provided an adequate amount of cartilage, and the patients did not need to worry about hypertrophic scars from a second surgical site. All patients were satisfied with their results.

**Meaning:** We recommend this material in Asian rhinoplasty, especially for augmentation procedures. This is the first report on the use of fresh frozen cadaveric cartilage in Asian rhinoplasty, and we demonstrated the safety and feasibility of this novel material.

among Asian Americans.<sup>7</sup> Dorsal augmentation, tip refinement, and tip elevation are major components in Asian rhinoplasties.<sup>8</sup>

Autografts are dominant materials for rhinoplasty of any ethnicity, but there are some limitations for Asians. Septal cartilage supply is often more limited in Asian patients than in White patients.<sup>4,8</sup> Conchal cartilage is curved in shape, and the amount is still limited. Costal cartilage provides enough volume, good long-term results, and lower complication rates.<sup>9,10</sup> However, it causes longer operative time, additional surgical costs, donor site morbidities, and potential hypertrophic scars.<sup>9,10</sup> It is worth mentioning that Asian skin is more susceptible to scarring, and Asian patients typically have A-B cup breasts, which cannot efficiently hide the scar of the donor site, resulting in peripheral cosmetic problems (Fig. 2).

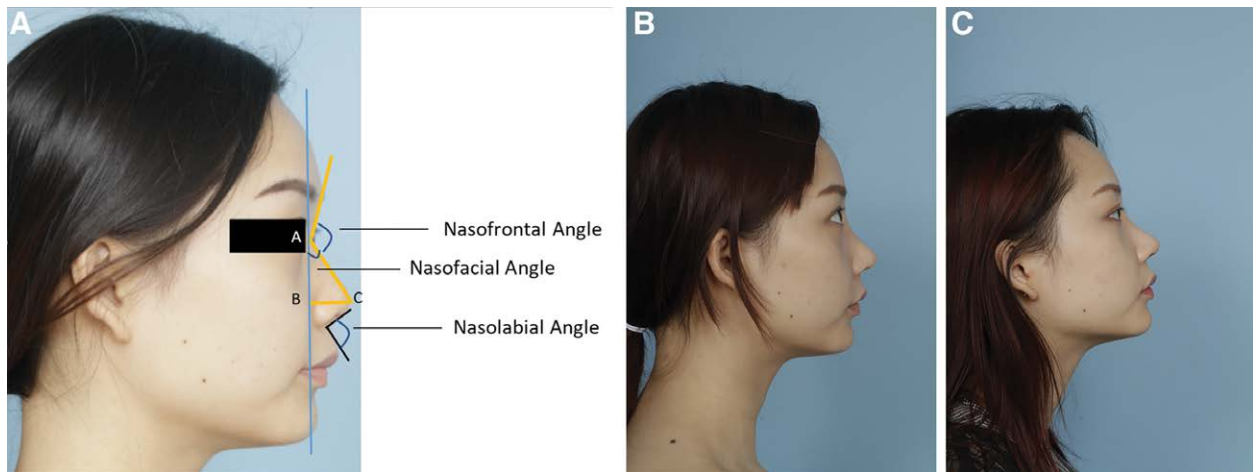
Previous concerns on cadaveric cartilage are high resorption and infection rates because irradiation was applied to sterilize the costal cartilage.<sup>9,10</sup> During the process of irradiation, the chondrocyte viability and the integrity of the cartilage were reduced.<sup>3</sup> The novel allograft provided by Musculoskeletal Transplant Foundation (Edison, N.J.) is processed without irradiation under high-quality sterility standards.<sup>5,10</sup>

Among our five patients, the modifications of the nasal tip, nasal dorsum, and radix are successfully maintained, as demonstrated by a comparison of photographs taken 2–4 months and 8–20 months after the surgery. While there may have been interpatient variability in anthropometric measurements, this study aimed to compare postoperative results at different follow-up points. Ethnic groups have variable standards of nasal beauty. Further, each patient had a unique nose and personalized goals for the surgery. As such, we did not compare our measurements with the ratios and angles of an “ideal” nose from other publications and did not compare the anthropometric measurements pre- and postoperatively.

Measurements obtained 8–20 months after surgery did not change significantly compared with measurements taken 2–4 months after surgery. The changes in

**Table 1. Patient Demographics and Medical History**

	Patient No.				
	1	2	3	4	5
Age at surgery (y)	21	41	23	30	22
Current smoking status	No	No	E-cigarettes	No	No
Medical history	Left cleft lip	No	No	Revision	No
Types of grafts made from the fresh frozen cartilage					
Spreader graft					✓
Columellar strut	✓	✓			✓
Tip elevation graft	✓	✓	✓	✓	
Septal extension graft		✓	✓	✓	
Dorsal onlay graft		✓	✓	✓	✓
Duration of follow-up (mo)	12	14	20	13	12
Complications	No	No	No	Minor scar	No



**Fig. 1.** A, Preoperative photos show a poorly defined nasal tip and a low set nasal bridge. B, Postoperative month 3 shows a higher nasal dorsum with good support after surgery. A crushed cartilage/temporoparietal fascia graft was placed on her dorsum. The radix was very flat, and the dorsum was low preoperatively, but they were elevated with good support as the patient desired. A small sheet of crushed cartilage graft was placed on her nasal tip. C, Postoperative month 6; patient achieved a projected nasal tip. There was no resorption and warping during her follow-up (Goode ratio = BC/AC).

**Table 2. Patient Measurements**

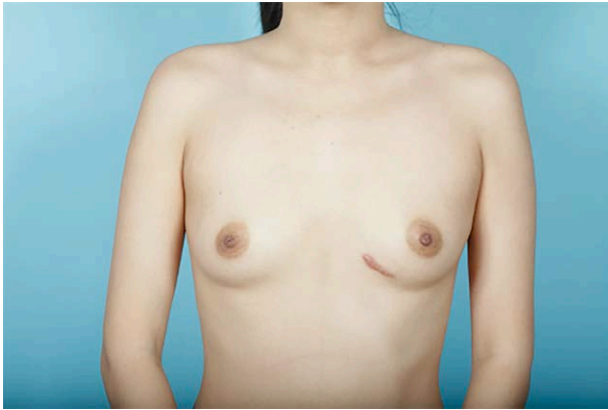
		Before Surgery	2–4 Months after Surgery	8–20 Months after Surgery	$\Delta =  \text{measurement}_{\text{visit1}} - \text{measurement}_{\text{visit2}} $
Subject 1	Nasofrontal angle	137.94	132.18	*	*
	Nasofacial angle	42.39	43.18	*	*
	Nasolabial angle	81.18	83.80	*	*
	Goode ratio	0.49	0.44	*	*
Subject 2	Nasofrontal angle	152.14	148.43	148.17	0.26
	Nasofacial angle	31.18	29.24	30.66	1.42
	Nasolabial angle	107.34	102.15	102.09	0.06
	Goode ratio	0.33	0.33	0.34	0.01
Subject 3	Nasofrontal angle	147.57	150.44	150.56	0.12
	Nasofacial angle	29.12	33.95	30.32	3.63
	Nasolabial angle	82.08	92.18	93.13	0.95
	Goode ratio	0.39	0.52	0.50	0.02
Subject 4	Nasofrontal angle	150.52	144.53	144.51	0.02
	Nasofacial angle	27.28	31.80	29.42	2.38
	Nasolabial angle	95.91	102.69	100.91	1.78
	Goode ratio	0.37	0.41	0.47	0.06
Subject 5	Nasofrontal angle	132.57	139.05	140.45	1.4
	Nasofacial angle	32.18	43.86	46.53	2.67
	Nasolabial angle	109.66	93.37	93.43	0.06
	Goode ratio	0.59	0.59	0.52	0.07

\*Subject 1 was lost to photographic follow-up, but she showed satisfaction on her FACE-Q questionnaire 1 year after the surgery.

the objective measurements on patients' noses ( $\Delta = |\text{measurement}_{\text{visit1}} - \text{measurement}_{\text{visit2}}|$ ) between follow-up visits were less than 1 degree. This confirms that CCA is a reliable material for Asian rhinoplasty with little concern for resorption or warping. Of note, the use of CCA is typically performed in the surgeon's office/clinic and the total expense was dramatically lower compared with using autologous costal cartilage because of the avoidance of the operating room and general anesthesia fee.

### CONCLUSIONS

Fresh frozen CCA is an excellent option for Asian rhinoplasty. Compared with current standards, it has the advantages of a more abundant supply, no donor site morbidity, shorter operative time, and lower surgical costs. Our case series also proves that CCAs are safe and yield satisfactory surgical outcomes. Further investigation involving a greater number of patients and longer follow-up time is needed.



**Fig. 2.** The postoperative photograph shows an elevated chest scar that cannot be covered by the left breast.

**Robert D. Galiano, MD, FACS**

Department of Surgery, Division of Plastic and Reconstructive  
Surgery  
Northwestern University Feinberg School of Medicine  
675 North Saint Clair Street, Suite 19-250  
Chicago, IL 60611  
E-mail: rgaliano@nm.org

#### DISCLOSURE

*The authors have no financial interest to declare in relation to the content of this article. The study received funding through the Musculoskeletal Transplant Foundation.*

#### PATIENT CONSENT

*The patient provided written consent for the use of her image.*

#### REFERENCES

1. Li D, An Y, Yang X. An overview of Asian rhinoplasty. *Ann Plast Surg.* 2016;77:S22–S24.
2. Moon KC, Han SK. Surgical anatomy of the Asian nose. *Facial Plast Surg Clin North Am.* 2018;26:259–268.
3. Choi JY. Complications of alloplast rhinoplasty and their management: a comprehensive review. *Facial Plast Surg.* 2020;36:517–527.
4. Fakhro A, Wagner RD, Kim YK, et al. Milestones of Asian rhinoplasty. *Semin Plast Surg.* 2015;29:213–218.
5. Mohan R, Shanmuga Krishnan RR, Rohrich RJ. Role of fresh frozen cartilage in revision rhinoplasty. *Plast Reconstr Surg.* 2019;144:614–622.
6. Klassen AF, Cano SJ, East CA, et al. Development and psychometric evaluation of the face-q scales for patients undergoing rhinoplasty. *JAMA Facial Plast Surg.* 2016;18:27–35.
7. American Society of Plastic Surgeons. Plastic surgery statistics report 2019. Available at <https://www.plasticsurgery.org/documents/News/Statistics/2019/plastic-surgery-statistics-full-report-2019.pdf>. Accessed April 15, 2020.
8. Yoo SH, Jang YJ. Rib cartilage in Asian rhinoplasty: new trends. *Curr Opin Otolaryngol Head Neck Surg.* 2019;27:261–266.
9. Rohrich RJ, Shanmugakrishnan RR, Mohan R. Rhinoplasty refinements: revision rhinoplasty using fresh frozen costal cartilage allograft. *Plast Reconstr Surg.* 2020;145:1050e–1053e.
10. Rohrich RJ, Abraham J, Alleyne B, et al. Fresh frozen rib cartilage grafts in revision rhinoplasty: a 9-year experience. *Plast Reconstr Surg.* 2022;150:58–62.