

From the <sup>1</sup>Professional Education and Research Institute, Roanoke, VA; <sup>2</sup>Brigham and Women's Hospital, Boston, MA; <sup>3</sup>Serena Group, Cambridge, MA; <sup>4</sup>Northwestern University Feinberg School of Medicine, Chicago, IL; <sup>5</sup>Strategic Solutions, Inc, Cody, Wyoming; <sup>6</sup>Lower Extremity Institute of Research and Therapy, Youngstown, OH; <sup>7</sup>Premier Surgical, Brick, NJ; <sup>8</sup>Shenandoah Lower Extremity Research Institute, Troutville, VA; <sup>9</sup>Martinsville Research Institute, Martinsville, VA; and <sup>10</sup>Angiogenesis Foundation, Cambridge, MA

Address correspondence to:

**Charles M. Zelen, DPM**

Professional Education and Research Institute  
222 Walnut Avenue  
Roanoke, VA 24016  
cmzelen@periedu.com

*Disclosure:* Dr. Zelen is the medical director of the Professional Education and Research Institute and has received research funds from Musculoskeletal Transplant Foundation (MTF; Edison, NJ) to conduct this clinical trial. Dr. Orgill is a consultant for MTF and receives research funding through grants to Brigham and Women's Hospital. Dr. Serena is the chief executive officer and medical director of Serena Group and has received research funds for clinical trials from MTF. Dr. Galiano is a consultant for MTF and receives research funding through grants to Northwestern University School of Medicine. Dr. Carter has received funds as a consultant for MTF. Dr. DiDomenico is the medical director of the Lower Extremity Institute of Research and Therapy and has received research funds for clinical trials from MTF. Dr. Kaufman is a consultant for MTF and has received funds for speaking engagements. Dr. Li is a consultant to MTF and has received funds for his consulting work. This study was funded by MTF, a 501c3 nonprofit foundation.

## Human Reticular Acellular Dermal Matrix in the Healing of Chronic Diabetic Foot Ulcerations that Failed Standard Conservative Treatment: A Retrospective Crossover Study

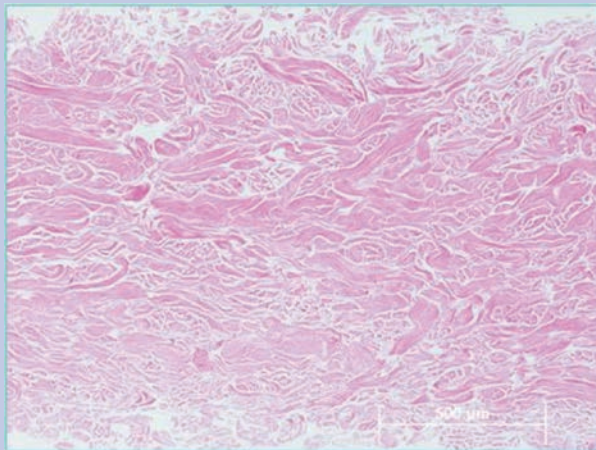
Charles M. Zelen, DPM<sup>1</sup>; Dennis P. Orgill, MD, PhD<sup>2</sup>; Thomas E. Serena, MD<sup>3</sup>; Robert D. Galiano, MD, FACS<sup>4</sup>; Marissa J. Carter, PhD, MA<sup>5</sup>; Lawrence A. DiDomenico, DPM<sup>6</sup>; Jarrod P. Kaufman, MD<sup>7</sup>; Jennifer Keller, DPM<sup>8</sup>; Nathan J. Young, DPM<sup>9</sup>; and William W. Li, MD<sup>10</sup>

**Abstract:** *Background.* Acellular matrices have been successfully used to heal indolent diabetic foot ulcers (DFUs). These tissues include allogenic dermis as well as xenograft dermis, pericardium, and small intestine submucosa. While all of these tissues show promise for healing DFUs, dermal-derived matrices have shown considerable potential. *Materials and Methods.* The authors retrospectively reviewed healing in patients with DFUs that failed the standard of care (SOC) treatment from a previous prospective randomized, controlled trial (RCT). That trial compared the efficacy of human reticular acellular dermal matrices (HR-ADMs) with the SOC. Of the 16 out of 20 patients who did not heal in the SOC group, 12 were eligible for crossover treatment with the HR-ADM. The authors studied the rate of complete healing in that specific cohort after 12 weeks of crossover treatment. *Results.* Of the 12 patients who were eligible for the HR-ADM, 10 (83%) achieved complete wound healing, with a mean healing time of 21 days to closure. The corresponding wound area reduction was from 1.7 cm<sup>2</sup> to 0.6 cm<sup>2</sup>. The mean product cost to closure was \$800/patient. *Conclusion.* This study further demonstrates the effectiveness of the HR-ADM in facilitating the closure of nonhealing DFUs refractory to SOC.

**Key words:** diabetic foot ulcers, dermal matrices, tissue repair, chronic ulcers, wound healing

Wounds Epub 2016 November 21

**D**iabetic foot ulcers (DFUs) are common complications, with nearly a quarter of people with diabetes experiencing at least 1 DFU in their lifetime.<sup>1</sup> The standard of care (SOC) for treating DFUs is offloading the wound, aggressive debridement, reduction of the wound bioburden, revascularization where indicated, and maintenance of moist wound-healing conditions.<sup>2-6</sup> Typical dressing options include collagen alginates, wound care gels, and antibacterial creams.



HR-ADM – Symmetrical Cut of Reticular Dermis

**Figure 1.** Hematoxylin and eosin stain showcasing the human reticular acellular dermal matrix (HR-ADM) is uniform throughout (symmetrical nature) and similar on both sides of the graft.

Despite excellent wound care, DFUs often take months to close, with many failing to do so. Prolonged wound healing leads to higher rates of infection and lower extremity amputation. Consequently, many interventions have been devised to accelerate wound closure, although only a few have undergone rigorous clinical trials. The literature demonstrates certain growth factors, as well as tissue-cultured skin substitutes, can improve healing of DFUs.<sup>7</sup> In addition, xenograft tissue matrices that have been studied, including dermis, small intestine submucosa, and pericardium, show promise in healing indolent wounds. The authors hypothesized human allogenic dermis, being the most analogous to a patient's tissue, would provide a suitable wound matrix to facilitate healing of chronic DFUs.

A randomized, controlled trial (RCT) was conducted to examine healing of indolent DFUs using a weekly application of aseptically processed human reticular acellular dermal matrix (HR-ADM; AlloPatch Pliable, Musculoskeletal Transplant Foundation [MTF], Edison, NJ) in conjunction with SOC compared to SOC alone. The results demonstrated that 16 of 20 (80%) patients healed with a weekly application of the HR-ADM, compared to 4 out of 20 (20%) patients who healed in the SOC arm after 12 weeks.<sup>8</sup>

After study exit, patients randomized to SOC were immediately offered the option to cross over and receive

the HR-ADM for up to 12 weeks. Twelve of the 16 total patients who did not improve with SOC returned for application of the HR-ADM while continuing SOC. The primary objective of this retrospective study was to evaluate the proportion of ulcers that went on to complete closure with a weekly crossover application of the HR-ADM over a period of up to 12 weeks. Secondary objectives included evaluating the healing trajectory and product cost to closure.

## Materials and Methods

**Study population.** Patients were deemed eligible for the study if they did not improve in the SOC arm of the HR-ADM RCT<sup>8</sup> (Western Institutional Review Board, November 13, 2014, #20142081). This included patients who had completed 12 weeks of SOC but whose ulcers did not heal and those who had exited the trial at 6 weeks because their DFUs failed to reduce in area by at least 50%, which was a criterion to ensure safety and the most compassionate care possible for all enrolled patients.<sup>9-12</sup>

Of the 16 patients who failed in the SOC arm, 12 returned to the clinic to receive a weekly application of the donated HR-ADM graft. The other 4 patients did not elect to receive the HR-ADM or were unable to receive it due to prior adverse events or serious adverse events that prevented grafting.

The study was approved by the Western Institutional Review Board, June 16, 2016 (#20161368) and allowed the investigators to review medical records of the entire original cohort from the time of study exit to current treatment. The study met applicable regulatory requirements in accordance with the provisions of the Declaration of Helsinki and in adherence to Good Clinical Practice. The first patient received a donated HR-ADM graft on February 10, 2015, and the last patient on February 12, 2016.

**Treatments.** At each clinic visit, the study ulcer was examined for presence of infection according to the guidelines of Woo and Sibbald.<sup>13</sup> If the examination suggested infection, a wound culture was taken with anaerobic and aerobic swabs of the suspected infected area, and appropriate systemic antibiotic treatment was administered until the infection clinically resolved. The wound was cleansed with sterile, normal saline solution and debrided as deemed necessary using a number 15 blade or curette to remove necrotic tissue. Hemostasis was obtained, digital photography of the wound was performed, and surface area was documented via acetate sheet tracing.<sup>14</sup>

**Table 1.** Wound and patient variables at study entry (N = 12) compared to the original standard-of-care (SOC) arm of the randomized, controlled trial (RCT; N = 20)

Variable	Failed SOC arm receiving HR-ADM (current study)	Original SOC arm (prior RCT)
Age	53 (10)	57 (10)
Race		
Caucasian	12 (100)	19 (95)
African American	0 (0)	1 (5)
Gender		
Male	8 (67)	12 (60)
Female	4 (33)	8 (40)
BMI	34 (8)	32 (7)
Smoker	4 (33)	6 (30)
Drinks alcohol	4 (33)	4 (20)
HbA1c (%)	7.1 (0.9)	7.8 (2)
Creatinine (mg/dL)	1.1 (0.4)	1.1 (0.4)
Wound area (cm <sup>2</sup> )	1.7 (1.7)	2.7 (2.3)
PAR at end of RCT <sup>a</sup>	25.3 (30.37)	—
Wound location		
Toe	5 (42)	7 (35)
Forefoot	5 (42)	7 (35)
Midfoot	1 (8)	2 (10)
Heel/ankle/hindfoot	1 (8)	4 (20)

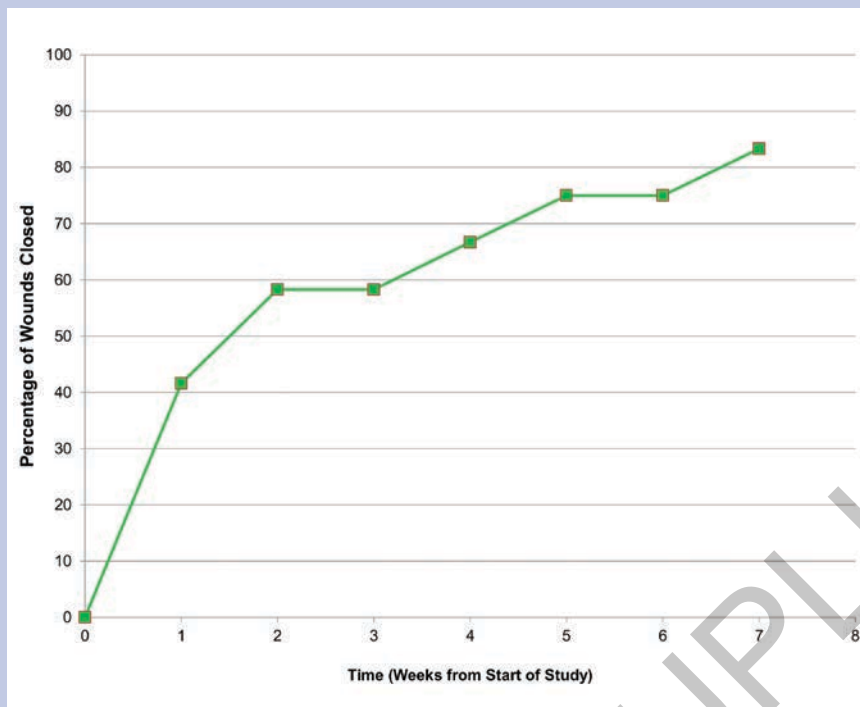
Continuous variables are reported as means and standard deviations, and categorical variables are reported as number and percentage.  
<sup>a</sup>The percentage area reduction (PAR) at the end of 12 weeks in the original RCT. HR-ADM: human reticular acellular dermal matrix; BMI: body mass index; HbA1c: glycated hemoglobin; PAR: percentage area reduction

The HR-ADM is an aseptically processed graft prepared from the deep layer of human dermis (Figure 1). It differs from most other human dermal matrices because it only contains the deeper reticular portion of the dermis without the papillary layer.

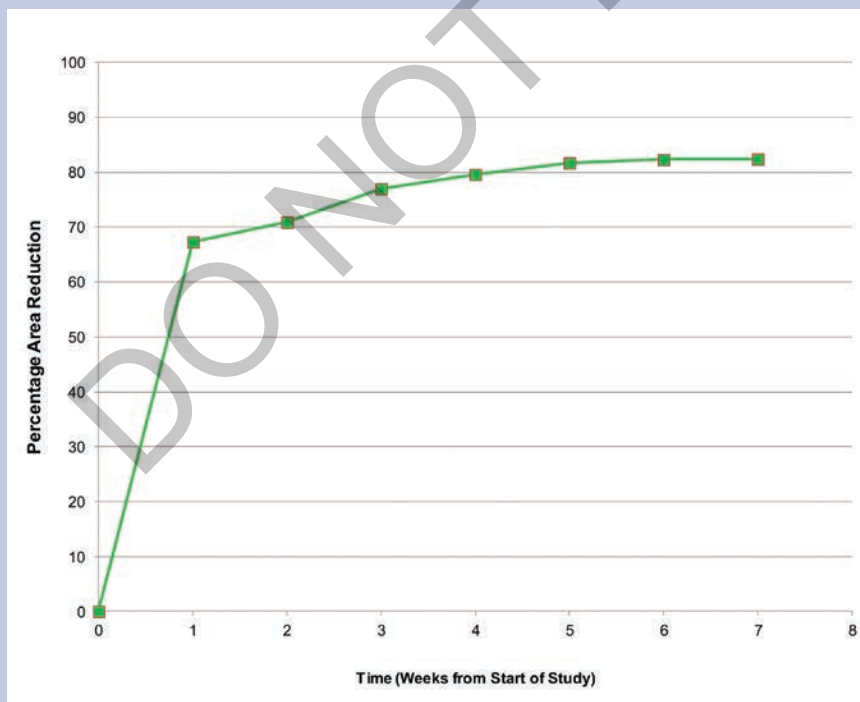
The tissue is obtained through a donation program coordinated by the largest tissue bank in the United States, MTE. The majority of donors were otherwise healthy and relatively young people who died in accidents or from sudden illness such as heart attack or stroke. Donors are thoroughly screened and tested before donation. The screening includes comprehensive medical and social histories including high-risk behaviors for transmissible diseases. Extensive testing and serology is also performed. In addition, exclusion criteria consist of potential donors with histories of conditions that may affect the quality and long-term performance of the tissue.

The tissue is aseptically processed by this organization without terminal sterilization. Human reticular acellular dermal matrix is available commercially through the tissue bank for use in offices, wound centers, and hospitals. The grafts are available in size-specific pieces to minimize cost and waste.

In preparation for treatment, each graft was trimmed to fit the wound if needed and pie-crusting or meshed to no greater than 1.5x to 1.0 with a number 15 blade. The graft was completely submerged in sterile saline for 5 to 10 seconds and then applied, with care taken to ensure complete adherence in the wound bed and coverage of the entire wound surface. A nonadherent dressing (ADAPTIC TOUCH, Acelity, San Antonio, TX) was used to cover the wound, followed by a moisture-retentive dressing (hydrogel bolster) and a padded 3-layer dressing (DYNA-FLEX, Acelity, San Antonio, TX) until complete epithelialization occurred. Wounds were off-loaded using a



**Figure 2.** Plot of percentage of wounds healed week by week during the study. After week 7, the percentage remained constant through week 12.



**Figure 3.** Trajectory of wound healing: plot of percentage area reduction week by week. After week 7, the percentage remained constant through week 12.

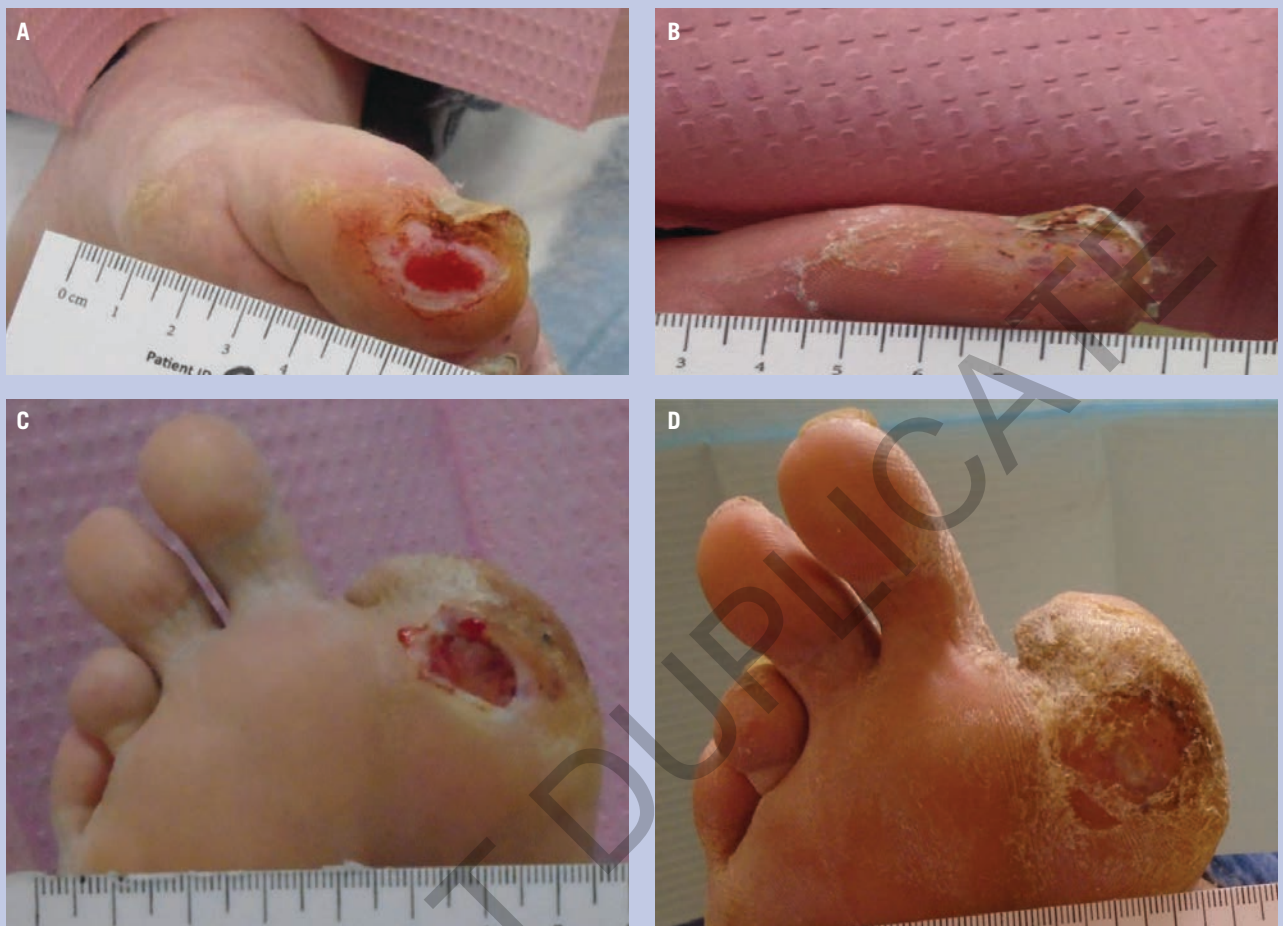total contact cast, removable cast walker (Royce Medical, Camarillo, CA), or similar generic device. Patients were examined weekly with continued weekly application of the HR-ADM for up to 12 weeks or until the wound healed.

*Study outcomes/Statistics.* The primary endpoint of the study was the proportion of wounds completely healed at 12 weeks. Secondary endpoints looked at the difference in wound area, in which paired values were used for each wound (baseline and end-of-study values) using the Wilcoxon signed-rank test; time-to-heal within 12 weeks was calculated using the Kaplan-Meier approach; the percentage area reduction (PAR) was calculated as  $PAR = ((A_1 - A_{12w})/A_1) * 100$ , where  $A_1$  was the area of the wound at study entry and  $A_{12w}$  was the area at 12 weeks; and mean product cost to wound closure, which was calculated by adding the costs of the applied HR-ADM. An intent-to-treat approach was used for all analyses. For missing observations, last observation carried forward was used. Study variables were summarized as means and standard deviations (SDs) for continuous variables unless the data were not normal. In such cases, medians were also reported. Results for categorical variables were presented as proportions or percentages. Statistical analysis was performed using PASW 19 software (IBM, Chicago, IL).

## Results

At entry to this retrospective study, patient characteristics ( $N = 12$ ) were similar to the overall patient characteristics in the SOC arm of the RCT, with a mean





**Figure 4.** Two patients who achieved healing with human reticular acellular dermal matrix (HR-ADM) graft. (A) Patient 1 exit from standard of care (SOC) after failed treatment; (B) and completely healed with one application of the HR-ADM graft. (C) Patient 2 exit from SOC after failure of treatment; and (D) completely healed after 4 applications of the HR-ADM graft.

age of 53 years (Table 1). Wounds were smaller in area (mean 1.7 cm<sup>2</sup>) at the beginning of this study compared to their original mean size at the beginning of the RCT (2.7 cm<sup>2</sup>), with a 25% mean reduction in area over the course of the RCT.

Following crossover, 10 of the 12 (83%) wounds achieved complete wound closure (Figure 2). The mean area of the DFUs reduced from 1.7 cm<sup>2</sup> to 0.6 cm<sup>2</sup> ( $P = 0.006$ ) at 7 weeks for the entire cohort (Figure 3), with a mean time to healing of 21.3 days (95% confidence interval, 11-31). Of the 10 patients who succeeded in healing, the healing was that of durable skin with complete epithelialization (Figure 4). Of the 2 patients whose wounds failed to heal during the 12-week period, 1 patient did not return after the initial visit and application of the HR-ADM and the other withdrew from the study after 5 weeks because the wound was not reducing in

area. At the end of the study period, the mean PAR was 82% (SD = 41) (Figure 3). The mean cost of the graft used to closure was \$800 (SD = \$790). No patient experienced adverse events or serious adverse events during treatment. All patients were provided with diabetic shoes and insoles donated by the tissue bank. When examining the results of the original RCT and the crossover cohort, the authors found that of the 32 patients who received the graft in total, 26 had healed completely for a combined healing rate of 81.3%.

## Discussion

This is a retrospective study of patients who, following the conclusion of the original RCT, had wounds that did not heal with SOC alone and who subsequently received HR-ADM as a crossover treatment in addition to continued SOC. Twelve out of 16 patients in the cohort

participated. The results showed the use of HR-ADM led to complete healing of 83% of the wounds, with a mean healing time of 21 days (Figure 2). Although this group of patients (N = 12) is smaller than the original group of 20, the percentages of healed wounds were similar (83% versus 80% in the RCT), which further supports the conclusions from the original RCT. The trajectory of closure was also similar to that demonstrated in the RCT (Figure 3). The combined healing rate for both studies was 81%.

In regard to product cost to closure, even though the HR-ADM was donated for this study, the value of the graft used was \$800. This amount takes into account the overall smaller wound size (1.7 cm<sup>2</sup>) at the start of the crossover study compared to the original RCT (2.7 cm<sup>2</sup> average wound size in the SOC cohort). The cost to closure for patients in the HR-ADM group of the original 12-week RCT<sup>8</sup> was \$1475 with an average wound size of 4.7 cm<sup>2</sup>. In a recently published 12-week trial<sup>15</sup> comparing a dehydrated human amnion/chorion membrane (dHACM; EpiFix, MiMedx, Marietta, GA), a bioengineered skin substitute (Apligraf, Organogenesis, Canton, MA), and SOC, the baseline wound areas of the first 2 groups were 2.6 cm<sup>2</sup> and 2.7 cm<sup>2</sup>, respectively, with corresponding mean costs to closure of \$2798 and \$8828, respectively. While it is difficult to compare cost to closure from different studies without also looking at initial wound size and other variables, it is clear the cost of the bioengineered skin substitute was far greater than the other options due to the fact that the tissue is only available in a single, large size. In contrast, HR-ADM and dHACM are available in multiple sizes, which minimizes waste.

Because HR-ADM grafts are available in size-specific packages, with the smallest graft measuring 1.5 cm x 1.5 cm, the majority of wounds healed with the smallest appropriate graft size. This reduced overall cost to closure compared with products available only in a single, large size. Cost is an important factor when clinicians choose among a myriad of advanced wound treatments. This study further supports HR-ADM graft use as not only a clinically effective but also a cost-effective intervention.

The HR-ADM used in this study originates from the deeper reticular layer of human dermis, which is known to be rich in collagens, elastin, and other extracellular matrix (ECM) components.<sup>16</sup> The dermis provides an open, uniform structure for cellular ingrowth and, during aseptic processing, specifically retains key ECM components such as collagens and elastin.<sup>8</sup> Furthermore,

reticular dermis has a basket-weave structure, similar to fetal tissue, which may facilitate regeneration rather than scar development.<sup>17,18</sup> By providing a wound with this open, uniform, organized framework, HR-ADM may stimulate the type of healing observed in this study.

In addition, HR-ADM has not undergone the terminal sterilization typically used in the majority of allografts available. Terminal sterilization can damage the basement membrane and elastin collagen fibers and subsequently affect the quality of the graft structure and integrity.<sup>19</sup> Aseptically processed HR-ADMs retain ECM components that play important roles in supporting cell migration, cell infiltration, and cell attachment.<sup>20-22</sup>

Study limitations include a small sample size and the fact that patients did not require follow-up since they were regular patients in the wound clinic; therefore, they were under no obligation to return and receive the complimentary graft.

## Conclusion

The crossover study showed a high healing rate (83%) among patients who received the HR-ADM with SOC who had failed to heal with SOC alone in the RCT. The mechanism by which the reticular dermis stimulates healing has yet to be fully investigated. However, with the results showing such marked success of the HR-ADM application, this novel approach may provide a cost-effective technology to treat patients with difficult-to-heal DFUs.

## References

1. Singh N, Armstrong DG, Lipsky BA. Preventing foot ulcers in patients with diabetes. *JAMA*. 2005;293(2):217-228.
2. Snyder RJ, Frykberg RG, Rogers LC, et al. The management of diabetic foot ulcers through optimal off-loading: building consensus guidelines and practical recommendations to improve outcomes. *J Am Podiatr Med Assoc*. 2014;104(6):555-567.
3. Lipsky BA, Berendt AR, Cornia PB, et al. 2012 Infectious Diseases Society of America clinical practice guideline for the diagnosis and treatment of diabetic foot infections. *Clin Infect Dis*. 2012;54(12):e132-e173.
4. European Wound Management Association. Wound bed preparation in practice: position document. [www.woundsinternational.com/media/issues/87/files/content\\_49.pdf](http://www.woundsinternational.com/media/issues/87/files/content_49.pdf). Published 2004.
5. Yamada T, Ohta T, Ishibashi H, et al. Clinical reliability and utility of skin perfusion pressure measurement in

- ischemic limbs—comparison with other noninvasive diagnostic methods. *J Vasc Surg*. 2008;47(2):318–323.
6. Ennis WJ, Borhani M, Meneses P. Re-establishing macrovascular flow and wound healing: beyond the vascular intervention. *Vasc Dis Manage*. 2008;5(3):74–80.
  7. Game FL, Apelqvist J, Attinger C, et al. Effectiveness of interventions to enhance healing of chronic ulcers of the foot in diabetes: a systematic review. *Diabetes Metab Res Rev*. 2016;32(suppl 1):154–168.
  8. Zelen CM, Orgill DP, Serena T, et al. A prospective, randomised, controlled, multicentre clinical trial examining healing rates, safety and cost to closure of an acellular reticular allogenic human dermis versus standard of care in the treatment of chronic diabetic foot ulcers [published online ahead of print April 12, 2016]. *Int Wound J*. doi: 10.1111/iwj.12600.
  9. Margolis DJ, Gelfand JM, Hoffstad O, Berlin JA. Surrogate end points for the treatment of diabetic neuropathic foot ulcers. *Diabetes Care*. 2003;26(6):1696–1700.
  10. Sheehan P, Jones P, Caselli A, Giurini JM, Veves A. Percent change in wound area of diabetic foot ulcers over a 4-week period is a robust predictor of complete healing in a 12-week prospective trial. *Diabetes Care*. 2003;26(6):1879–1882.
  11. Snyder RJ, Cardinal M, Dauphinée DM, Stavosky J. A post-hoc analysis of reduction in diabetic foot ulcer size at 4 weeks as a predictor of healing by 12 weeks. *Ostomy Wound Manage*. 2010;56(3):44–50.
  12. Lavery LA, Barnes SA, Keith MS, Seaman JW Jr, Armstrong DG. Prediction of healing for postoperative diabetic foot wounds based on early wound area progression. *Diabetes Care*. 2008;31(1):26–29.
  13. Woo KY, Sibbald RG. A cross-sectional validation study of using NERDS and STONEES to assess bacterial burden. *Ostomy Wound Manage*. 2009;55(8):40–48.
  14. Wendelken ME, Berg WT, Lichtenstein P, Markowitz L, Comfort C, Alvarez OM. Wounds measured from digital photographs using photodigital planimetry software: validation and rater reliability. *Wounds*. 2011;23(9):267–275.
  15. Zelen CM, Serena TE, Gould L, et al. Treatment of chronic diabetic lower extremity ulcers with advanced therapies: a prospective, randomised, controlled, multi-centre comparative study examining clinical efficacy and cost. *Int Wound J*. 2016;13(2):272–282.
  16. Simpson DG. Dermal templates and the wound-healing paradigm: the promise of tissue regeneration. *Expert Rev Med Devices*. 2006;3(4):471–484.
  17. Mast BA. The skin. In: Cohen IK, Diegelmann RF, Lindblad WJ (eds). *Wound Healing: Biochemical and Clinical Aspects*. Philadelphia, PA: WB Saunders, 1992: 344–355.
  18. Rolfe KJ, Grobbelaar AO. A review of fetal scarless healing [published online ahead of print May 17, 2012]. *ISRN Dermatol*. 2012;2012:698034. doi: 10.5402/2012/698034.
  19. Mrázová H, Koller J, Fujeříková G, Babál P. Structural changes of skin and amnion grafts for transplantation purposes following different doses of irradiation. *Cell Tissue Bank*. 2014;15(3):429–433.
  20. Ruszczak Z. Effect of collagen matrices on dermal wound healing. *Adv Drug Deliv Rev*. 2003;55(12):1595–1611.
  21. Deakin NO, Turner CE. Paxillin inhibits HDAC6 to regulate microtubule acetylation, Golgi structure, and polarized migration. *J Cell Biol*. 2014;206(3):395–413.
  22. Reinke JM, Sorg H. Wound repair and regeneration. *Eur Surg Res*. 2012;49(1):35–43.